

**FINE NEEDLE ASPIRATION CYTOLOGY (FNAC) IN
DIAGNOSIS OF TUMORAL CALCINOSIS, A REPORT
OF THREE CASES**

**A. A. Mohamedani MRCPATH¹, Ahmed E. ElSheik FRCS², Faisal Nugud MD³
& Osman Taha Mohamed Osman FRCS⁴**

1. Professor of pathology ,
 2. Associate professor of Surgery
 3. Assistant professor of Surgery
 4. Professor of Surgery
- All from University of Gezira, Faculty of Medicine, Sudan

ABSTRACT

Introduction: Tumoral calcinosis (T.C.) is very rare and generally of unknown aetiology characterized by calcific deposits in the soft tissues. Commonly seen in the second decade of life (reported age range 15 months to 83 years). We are reporting 3 cases of T. C. who were initially diagnosed by FNAC. Two of the 3 cases were female siblings who were referred to us as possible cases of recurrent fibrosarcomas following surgical excision.

Case reports: (1) Two female siblings aged 17 and 14 years complaining of large swelling in the upper outer right thigh and the left outer upper thigh around the hip joints respectively. There was no limitation of movement. The masses recurred within a short period after total excision. Neither specimen was subjected to histopathology. Clinical examination showed two masses each approximately 30cm maximum diameter and 10 cm width. In addition the younger sister showed an additional mass 4.5 cm in the outer aspect of her right elbow.

(2) 18 months old female child, unrelated to the above two cases, presented with an egg-sized mass in the mid-lateral aspect of her right thigh cystic and mobile. There is a history of quinine injection in the same area. No positive family history of a similar condition. All three cases showed normocalcaemia and hyperphosphataemia with specks of calcification on x - ray and cysts in ultrasound. FNAC showed structureless gung , calcium granules and inflammatory cells including foreign body type multinucleated giant cells. Histopathology confirmed the diagnosis of T. C.

Discussion: Described the three types of T. C. (familial, idiopathic, and that in patients of chronic renal failure on dialysis). The differential diagnoses were also discussed as well as lines of management such as Ca⁺⁺ supplementation, phosphate restriction, acetazolamide, parathyroidectomy and the treatment of choice is total surgical excision.

To our best knowledge this is the first time to report the use of fine needle aspiration cytology in the diagnosis of T. C. in Sudan.

INTRODUCTION

Tumoral calcinosis (T.C.) is a rare condition of unknown aetiology characterized by calcific deposits in the soft tissues mainly around large joints .It is most commonly seen in the second decade of life but may be seen in younger patients with an age range 15 months to 83 years. Only about 250 cases of T.C. have been reported in the English language literature, the youngest patient being 15 months old. We report 3 cases of T.C. who were initially diagnosed by fine needle

EDITORIAL

aspiration cytology (FNAC). Two of the 3 cases were female siblings who were referred to us as possible cases of recurrent fibrosarcomas following surgical excision.

CASE REPORTS

Case 1: A female 17 years old, single and unemployed. Her main complaint was a swelling in the upper outer right thigh around the hip joint. It was preceded by a severe continuous pain in the same area two months prior to the appearance of the swelling. There was no history of trauma, fever, cough or weight loss. There was no limitation of movement in the right hip joint. She reported a total excision of the mass in her local hospital about a year ago. Unfortunately the specimen was not sent to any pathology laboratory and was thrown away. The swelling recurred rapidly, but this time was not preceded by pain. Local examination revealed a swelling involving the whole of the lateral aspect of the right upper thigh with a longitudinal surgical scar and a maximum diameter of 30 cm. and a width of 10 cm (Figure 1). It was firm and slightly mobile. A provisional diagnosis of a recurrent fibro- or rhabdomyosarcoma was made.

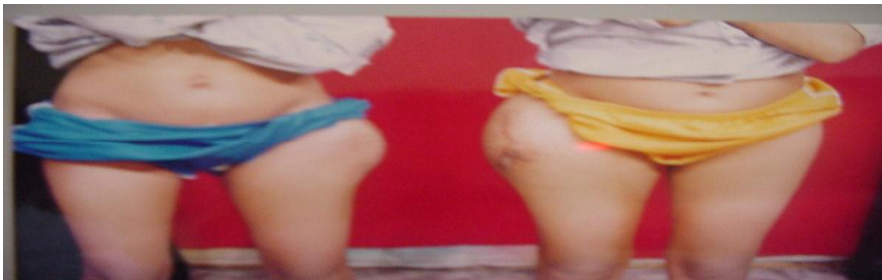

Fig 1: The thigh swelling of the two female siblings

Case 2: A female 14 years old, unemployed and is the younger sister of case 1. Her complaint was similar to her sister except that the swelling was around her left upper thigh. General and local examination was not different from her sister (Figure 1) and the mass was removed in the same local hospital and then recurred within a very short period. In addition, she developed another swelling in the outer aspect of her right elbow with a maximum diameter of 4.5 cm. A similar provisional diagnosis to that of her sister was made.

Case 3: An 18 months old female child, unrelated to the above two cases, presented with a mass in mid lateral aspect of her right thigh. Examination revealed an egg-shaped swelling, slightly cystic and mobile. There was a history of quinine injections delivered to the same site. No family history of a similar condition was given by any of the three cases.

INVESTIGATIONS

Apart from normal routine general investigations, the following tests were performed to each of the three cases: Serum calcium and phosphate, ultrasound and plain X-rays of the swellings. The results are displayed in the table.

Table: Serum calcium, phosphate, X-rays and ultrasounds of the 3 cases

EDITORIAL

Investigation	Normal range	Case 1	Case 2	Case 3
Serum calcium	8.1-10.4 mg/dl	9.4 mg/dl	9.5 mg/dl	9.1 mg/dl
Serum phosphate	4.0-7.0 mg/dl	9.0 mg/dl	8.5 mg/dl	7.0 mg/dl
Plain X-ray	_____	Specks of calcification	Specks of calcification	Specks of calcification
Ultrasound	_____	Cystic changes	Cystic changes	Cystic changes

Fine needle aspiration cytology (FNAC):

Was performed for all the swellings in the three cases. Aspiration revealed a thick pale brown whitish chalky material. Cytology showed a structureless mass with calcium granules and mononuclear inflammatory cells as well as multinucleated foreign body type giant cells. These features were reported as consistent with tumoral calcinosis.

NB: Appropriate samples were obtained from both siblings and their parents for future HLA and genetic studies.

Operative and histopathological findings:

The thigh swelling of case three was easily removed in toto. The hip masses of the other two cases were difficult to remove as they were having prolongations between the muscles extending close to the bone but not involving the joints; hence it was not possible to get them intact and both were ruptured.

Gross examination:

The masses of the first 2 cases had similar sizes to those described previously. They were lobulated and cut surfaces showed multiple cysts with thick dense

EDITORIAL

walls and containing brownish chalky material (Figure 2) . The third case displayed a single cystic cavity containing whitish chalky material.

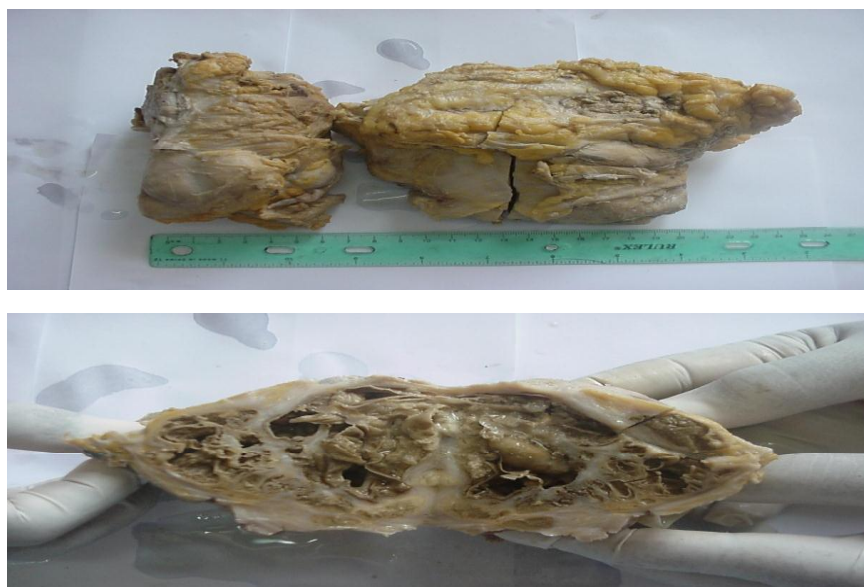


Fig (2): Gross appearance of the two masses plus cut surface

Histopathology:

Histopathological examination was similar in the three cases: showing intensive foci of calcification, calcific material in the cysts which were surrounded by thick fibrous and collagenous tissue with mononuclear cells and multinucleated foreign body type giant cells.

The three patients had an uneventful recovery. The two first cases were put on acetazolamide, a carbonic anhydrase inhibitor. All were followed for up for 6 months and none showed any evidence of recurrence.

DISCUSSION

Tumoral calcinosis was a term first introduced by Incan et. al. in 1943 ⁽¹⁾ .It seems to occur in 3 types: 1-An autosomal recessive familial type with hyperphosphataemia, normocalcaemia and an increased level of 1, 25-dihydroxyvitaminD. 2-An idiopathic type without hyperphosphataemia or metabolic abnormality. 3- Seen in patients receiving dialysis for renal failure, usually secondary to hyperparathyroidism , especially in those treated by Vit.D. T.C. is characterized by massive subcutaneous soft tissue deposits of calcium phosphate near large joints such as the hip, the shoulder and elbow in addition to wrist, feet and hands. Men and non-whites are affected more than women and Caucasians. A family history is apparent in 30-40% in those with an autosomal recessive pattern of inheritance ⁽²⁾ . The first two cases seem to fit with this recessive type of inheritance. Case three more or less fits with the idiopathic type. In a series of 111 reported by Pakasa and Kalengayi, 108 were healthy with 57% of the cases having the disease around the hip joint ⁽³⁾ . This is true in our first two cases as the lesions were around the hip joints

EDITORIAL

in both .Recurrence after surgery was 7% in this large series (111 cases) but in the first two cases, presented 94

in this study, recurrence occurred quite rapidly following surgery. It has been reported that T.C. occurs in about 1% of haemo or peritoneal dialysis patients. The pathogenesis of T.C. is poorly understood but thought to be due to calcium/phosphate metabolic abnormality. It has been suggested that a Ca x P product greater than 70 may facilitate the deposition of calcium. ^(4,5) This suggestion holds true for the three cases in this present study. The disease is usually painless unless nerves are involved. ⁽⁶⁾ The differential diagnosis includes: Calcinosis circumscripta, calcinosis universalis, milk-alkali syndrome and hypervitaminosis D ⁽⁷⁾.

Kazuhiro Ogino et .al. found a good correlation between ultrasonography (US), C.T. scan and macroscopical findings.They found in US cystic areas with thin

walls, cystic areas with thick walls and fluid levels as well as stone-like areas ⁽⁸⁾ In the first 2 cases presented in this study the differential diagnosis included soft tissue tumours, specially sarcomas.This is more so when recurrence occurs after surgical excision and specially when no histopathological studies are made.To the best of our knowledge these are the first cases of tumoral calcinosis to be diagnosed by FNAC. The appearance of the aspirates and the cytological findings were very characteristic .As for management, surgical excision is the treatment of choice provided that the lesion is completely removed ⁽⁹⁾. Other lines of management include: control of hyperparathyroidism, trying to correct Ca/P imbalance by a low phosphate diet or using phosphate binders, calcium adminstration and acetazolamide. In those with painful lesions, Ca x P above 70 and a PTH level less than 20 pmol/L total parathyroidectomy may be the treatment of choice. ^(9, 10). It is remarkable that the first two cases of this present study did very well after surgical treatment and administration of acetazolamide .There might be some association between the I/M quinine injections and T.C. in case 3, but it is remarkable we do not see such cases of T.C. inspite of the wide use of I/M injections, specially quinine, in our medical practice. Slavin RE et.al. ⁽¹¹⁾ suggested that repeated trauma and bleeding, with a disordered reparative process, are possible causes of T.C. Majeed SA ⁽¹²⁾ reported the possible association of T.C. with chronic recurrent multifocal osteomyelitis, an uninfective condition of unkown aetiology.

REFERENCES

1. Umesh Bhagia, Styles L. Bertrand, and Henry J. Iwinski. Tumoral calcinosis in an infant.
2. Nedim Savaci , M.D.; Mustafa Cihat Avunduk, M.D; Zekeriya Tosun, M.D. ; Mubin Honuter M.D. Hyperphosphataemic Tumoral Calcinosis .Plastic and reconstructive surgery 2000 ; 105 : 162-165.
3. Pakasa NM, Kalangayi RM.Tumoral Calcinosis: a clinicopathological study of 111 cases with emphasis on the earliest changes. Histopathology. 1997 Jul; 31(1): 18-24.
4. Echenique-Elizondo, Sanz Jaka. Tumoral Calcinosis on secondary hyperparathyroidism in chronic renal failure. <http://www.sc.ehu.es/scrwwsr/kirurgia/Kirurgia2003c/calcinosis.ht ml>

EDITORIAL

5. Ben Taarit C, el Younsi F , Turki S, Mestri M, Ben Maiz H. Tumorous calcinosis in haemodialysis; anatomo-clinical study apropos. Of 3 cases. *Nephrologic*. 2001; 22 (7): 349-52.
6. Gofan F, Garcias Cmbalia A, Segur JM, Opperheimer F. Carpal tunnel syndrome secondary to uraemic tumoral calcinosis. *Rheumatology (Oxford)* 2002; 41(6): 701-5.
7. Pola E, Pola R, Gaelani E, De Santir E . Tumoral calcinosis. *Lancet*. 2002; 359 (9320): 1818.
8. Kazuhiro Ogino, RMS, Shigenori Yabu, Hiroyuki Shimizu, Shigeaki Wakita, Masakliko Tei and Toyotsugu Ota. A case of so-called tumoral calcinosis of the gluteal region: Correlation of U.S. findings with appearance in CT and macroscopic images. <http://wwwsoc.nii.ac.jp/jsum/magazine/1996/23-10.html>
9. Reginato AJ, Tamesis E, Netter P. Familial and clinical aspects of Ca/P deposition disease. *Curr Rheumatol Rep*. 1999; 1 (2): 11220.
10. E G Lufkin, D M Wilson, L H Smith et.al. Phosphorus excretion in tumoral calcinosis: response to parathyroid hormone and acetazolamide. *Journal of clinical endocrinology and metabolism* , Vol 50 , 648-653 , copyright 1980 by
11. Slavin RE, Wen J, Kumar D, et.al: Familial tumoral calcinosis. A clinical, histopathologic and ultrastructural study with an analysis of its calcifying process and pathogenesis. *Am J Surg Pathol* 17:788802,1993
12. Majeed SA: Chronic recurrent multifocal osteomyelitis associated with tumoral calcinosis. *J Bone Joint Surg Br* 76:325-327, 1994.