

Ectopic Thyroid Presenting as a Sublingual Mass in a Sudanese Girl

Wail N Osman¹ and Osman M Elmustafa²

1. Consultant ORL H & NS and assistant professor, Department of Surgery, Faculty of Medicine, University of Gezira
2. Professor and senior consultant of ORL, H & N Surgery, Department of Surgery, Faculty of Medicine, University of Gezira

Correspondence: Wail Nuri Osman, MD, Otorhinolaryngologist, Assistant professor, Department of Surgery, Faculty of medicine, Gezira University, P O Box 20, Medani, Sudan. Tel: 0128151911. E-mail: wailnuri2000@yahoo.co.uk

Abstract:

Although extremely rare, the presence of ectopic thyroid tissue in the sublingual region should be considered in the differential diagnosis of masses in the cervical region. Diagnosis is confirmed by Fine-needle Aspiration\Biopsy Cytology and exclusion of malignancy by histopathologic analysis of the lesion. In general, surgery should not be attempted before radioisotope scan is obtained as this might be the only functioning thyroid tissue.

This is a rare case of ectopic thyroid in the sublingual region reported in a Sudanese girl; it was diagnosed after radioisotope thyroid scan and proved to be the only functioning thyroid tissue.

Keywords: Ectopic thyroid, Sublingual, Head and neck neoplasms,

Introduction:

Ectopic thyroid tissue is a rare condition resulting from developmental defects at early stages of thyroid gland embryogenesis, during its passage from the floor of the primitive foregut to its final pre-tracheal position^(1, 2, 3). It is frequently found around the course of the thyroglossal duct or laterally in the neck which may or may not coexist with a normal thyroid gland, as well as in distant places such as the mediastinum and the subdiaphragmatic organs^(4, 5, 6). Although most cases are asymptomatic, symptoms related to tumor size and its relationship with surrounding tissues may also appear. Any disease affecting the thyroid gland may also involve the ectopic thyroid, including malignancy. Hence, it should be considered in the extensive differential diagnosis of neck masses.

Failure in the median descent often results in a lingual thyroid^(7, 8). In some rare cases, the lack of merging of the lateral cell clusters with the median can cause a lateral ectopic thyroid gland^(4, 7). When this occurs, thyroid tissue is located in the submandibular region. (4, 7, 8, 9, 10)

Case Report:

A seven years old Sudanese girl presented with a neck swelling in the submental region. The swelling was noticed by her parents few months after birth. The condition was otherwise asymptomatic. There were no symptoms regarding the mouth, ears or nose and no airway or swallowing difficulties. There were no other systemic or general symptoms.

Physical examination revealed a rounded neck swelling in the sublingual region, measuring about 3 cm in diameter, not hot or tender, firm, with smooth surface, attached to deep structure, moves with swallowing and protrusion of the tongue and not compressible or pulsatile. No thyroid was felt in its normal position or any other cervical swellings (figure 1).

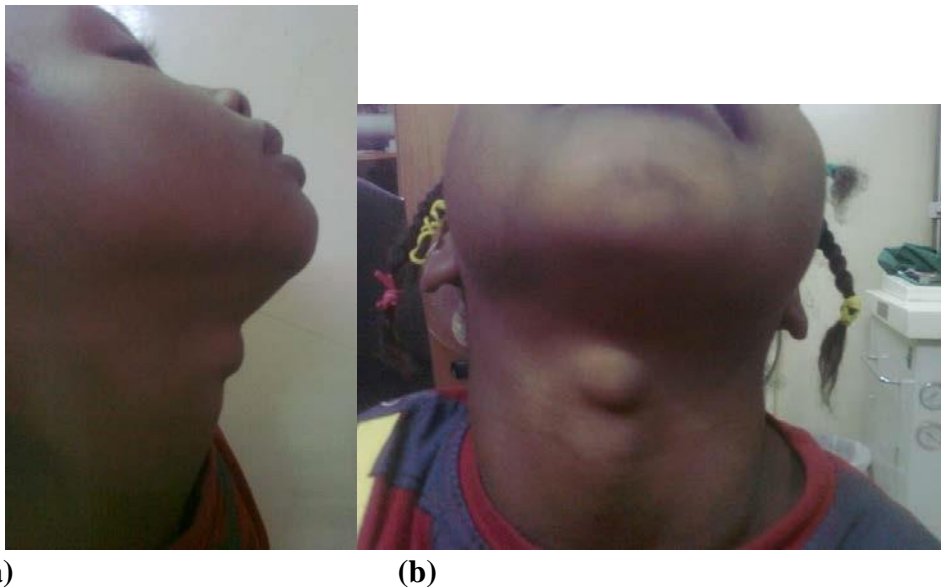

Figure 1: Patient's photo showing the mass; (a) profile and (b) front view. A provisional diagnosis of a thyroglossal duct cyst, supra hyoid type was made. A fine-needle aspirate of the swelling showed proteinaceous background and clumps of bland follicular cells, features were suggestive of thyroglossal cyst. There was no evidence of malignancy.

Thyroid radioisotope scan and uptake with ^{99m}Tc pertechnetate 52 MBq showed intense uptake in the submandibular area which corresponds to the clinical palpable mass suggestive of sublingual thyroid. The percentage of thyroid uptake was normal. No other thyroid tissue was seen in the normal anatomical position of the thyroid (Figure 2). So the diagnosis became clearly of ectopic, sublingual, thyroid and more interesting it was the only functioning thyroid tissue.

Further studies included thyroid hormones which were within normal limits. Full blood count showed low haemoglobin of 55% with peripheral blood picture suggestive of iron deficiency anaemia.

EDITORIAL

The condition was explained to the parents and they were advised not to seek surgical treatment.

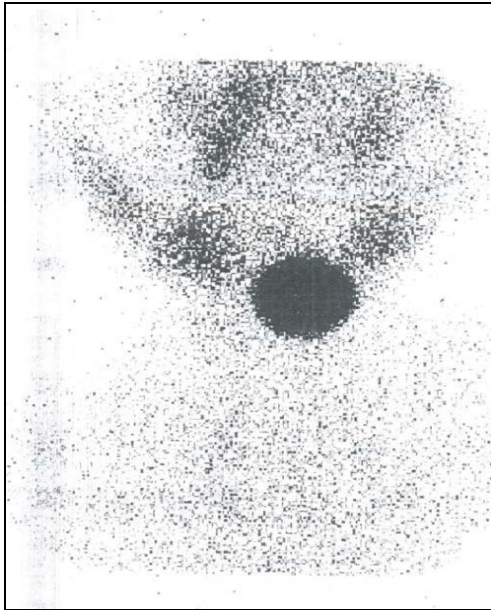


Figure 2: Thyroid radioisotope scan and uptake showing intense uptake in the submandibular area which corresponds to the clinical palpable swelling suggestive of sublingual thyroid.

Discussion:

Ectopic thyroid is defined as thyroid tissue not in the normal anatomical position; anterolateral to the second, third and fourth tracheal rings^(1, 3, 4, 5, 10). It is the most common form of thyroid dysgenesis, accounting for 48–61% of all cases.⁽⁷⁾

The first case of ectopic thyroid was published in 1869 by Hickman, who described a lingual thyroid in a newly-born baby that underwent suffocation 16 hours after birth as a consequence of a tissue mass that caused upper airway obstruction.^(4, 11)

Ectopic thyroid tissue usually occurs in the midline, from the foramen caecum to the mediastinum as a result of abnormal median migration and is rarely present lateral^(1, 5, 9, 10, 11). Ectopic thyroid along the line of the cervical midline can be explained by non-migration or by excessive migration of thyroid tissue.^(1, 4, 5, 12) A lingual location is most common, accounting for 90% of the reported cases^(1, 4, 5, 6, 10, 11, 12). Other rarely involved sites are the mediastinum, lungs, porta-hepatis, duodenum, esophagus, heart, breasts, and intra-tracheal area⁽¹⁻¹²⁾. Presence of ectopic thyroid tissue in the submandibular region is extremely rare.^(1, 4, 8, 9, 10, 11)

From a clinical standpoint, patients present with a cervical mass which is palpable, mobile and painless that can be associated with thyroid hyperfunction or hypofunction^(1 - 11). Diseases that affect the normal thyroid gland can also affect the ectopic tissue, but benign or malignant neoplastic alterations that affect the ectopic

EDITORIAL

thyroid tissue are very rare ^(3, 4, 5, 6, 8). Less than 1% of ectopic thyroids are reported to have malignant transformation.

Although rare, diagnosis of ectopic thyroid should be considered in the investigation of sublingual, lingual and submandibular masses ^(1, 5, 6, 8–11). In the neck, ectopias are clinically indistinguishable from other pathologies, such as lymph nodes, tumors of the salivary glands or cysts ⁽⁹⁾. In addition to clinical history and physical examination, FNAC, ultrasonography and thyroid scan are useful for initial assessment. ^(5, 11)

Generally, diagnosis of ectopic thyroid is confirmed by fine-needle aspiration biopsy and differentiation between a benign and a malignant lesion is made only through histological assessment ^(3, 5, 6, 8, 13).

The treatment of ectopic thyroid depends on factors such as mass size, local symptoms, age of the patient, functional status of thyroid gland and complications (ulceration, hemorrhage and neoplasia) ^(6, 10). Surgical excision is to be planned only after confirmation that this is not the only functioning thyroid tissue and histopathological evaluation of the mass.

In the current case the ectopic thyroid was in the sublingual region which is extremely rare. Thus, clinically the first impression of such a congenital, solitary and painless swelling pointed towards thyroglossal duct cyst, supra hyoid type. FNAC in this case matched that provisional diagnosis. Radio-isotope scan proved that the mass was the only functioning thyroid tissue. Surgery was not considered and the condition was explained to the parents.

Conclusion:

Cases of ectopic thyroid in the sublingual region are extremely rare and should be suspected in patients with cervical masses, with or without normally located thyroid. Workup should include, FNAC and ultrasonography. radioisotope scanning is particularly indicated before any surgical intervention, as the swelling may be the only functioning thyroid tissue.

References:

1. Osman M Elmustafa, Mohammed El M Abdelkarim, Wail N Osman. A Lingual Thyroid Associated With Congenital Profound Sensorineural Hearing Loss: Case report. *GJHS*. June 2011; Vol 7 (1): 82 – 86.
2. J A Bersaneti, R D P Silva, R N Ramos, M Matsushita and L R Mo Souto. Ectopic Thyroid Presenting as a Submandibular Mass. *Head Neck Pathol*. 2011 March; 5(1): 63–66. doi: 10.1007/s12105-010-0209-z PMID: PMC3037464
3. Noussios G, Anagnostis P, Goulis DG, Lappas D, Natsis K. Ectopic thyroid tissue:

EDITORIAL

- anatomical, clinical, and surgical implications of a rare entity. *Eur J Endocrinol.* 2011 Sep; 165(3):375-82. Epub 2011 Jun 29.
4. Huang TS, Chen HY. Dual thyroid ectopia with a normally located pretracheal thyroid gland: case report and literature review. *Head Neck.* 2007;29(9):885–888. doi: 10.1002/hed.20604.
 5. Kousta E, Konstantinidis K, Michalakis C, et al. Ectopic thyroid tissue in the lower neck with a coexisting normally located multinodular goiter and brief literature review. *Hormones (Athens)* 2005;4(4):231–234
 6. Nasiru Akanmu I, Mobolaji Adewale O. Lateral cervical ectopic thyroid masses with eutopic multinodular goiter: an unusual presentation. *Hormones (Athens)* 2009;8(2):150–153.
 7. Choi JY, Kim JH. A case of an ectopic thyroid gland at the lateral neck masquerading as a metastatic papillary thyroid carcinoma. *J Korean Med Sci.* 2008;23(3):548–550. doi: 10.3346/jkms.2008.23.3.548.
 8. Mace AT, McLaughlin I, Gibson IW, et al. Benign ectopic submandibular thyroid with a normotopic multinodular goitre. *J Laryngol Otol.* 2003;117(9):739–740. doi: 10.1258/002221503322334648.
 9. Babazade F, Mortazavi H, Jalalian H, et al. Thyroid tissue as a submandibular mass: a case report. *J Oral Sci.* 2009;51(4):655–657. doi: 10.2334/josnusd.51.655.
 10. Abellán Galiana P, Cámara Gómez R, Campos Alborg V, et al. Dual ectopic thyroid: subclinical hypothyroidism after extirpation of a submaxillary mass. *Rev Esp Med Nucl.* 2009;28(1):26–29. doi: 10.1016/S0212-6982(09)70213-7
 11. Amoodi HA, Makki F, Taylor M, et al. Lateral ectopic thyroid goiter with a normally located thyroid. *Thyroid.* 2010;20(2):217–220. doi: 10.1089/thy.2008.0410.
 12. Zieren J, Paul M, Scharfenberg M, et al. Submandibular ectopic thyroid gland. *J Craniofac Surg.* 2006;17(6):1194–1198. doi: 10.1097/01.scs.0000246502.69688.60.
 13. Feller KU, Mavros A, Gaertner HJ. Ectopic submandibular thyroid tissue with a coexisting active and normally located thyroid gland: case report and review of literature. *Oral Surg Oral Med Oral Pathol Oral Radiol Endod.* 2000;90(5):618–623. doi: 10.1067/moe.2000.108804.