

Diagnosis of gall bladder agenesis is a pitfall

Sami MahjoubTaha¹, Mohammed Ahmed Ibnuof², AbdAlMagid Masaad²,
Mohamed EL-Imam Mohammed³, Kamal Mohammed ⁴, Gamal Mustafa¹, Daaa
Eldinn Yaseen¹

1. MD, General surgeon, assistant professor, University of Gezira, Faculty of Medicine
 2. FRCS, Gastroenterologist, professor of GI surgery, University of Omdurman, Faculty of Medicine
 3. MD, Urologist and general surgeon, professor of urology, University of Gezira, Faculty of Medicine
 4. MD, General surgeon, Ibn Sina Hospital
- Correspondent author: Sami Mahjoub Taha. E- mail: samimahj@gmail.com**

Introduction:

A wide range of gall bladder congenital anomalies have been noticed and reported by physicians and surgeons in the last decades. A very rare congenital anomaly at the level of the biliary system is the complete absence of the gall bladder. It is thought to occur in approximately 1 in 6,000 live births. It is often asymptomatic and often found at postmortem.⁽¹⁾ **Key words:** Gall bladder agenesis, Sudan

Case Report:

A female of 60 years presented with right hypochondrial pain triggered by fatty meal and vomiting. There was a history of fluctuant jaundice. Clinical examination revealed no abnormal findings.

The investigations conducted included complete hemogram; renal functions test and Liver functions test were normal. Abdominal ultrasound showed contracted gall bladder with multiple stones and the common bile duct (CBD) was dilated with 2 cm stone in the distal end. ERCP revealed dilated CBD with a large stone difficult to be removed.

The plan of management was diverted to be open cholecystectomy and exploration of common bile duct. Intraoperative findings were absent gall bladder (Only bud-like structure) and Postero-laterally situated common bile duct in the free border of the lesser omentum (Figure 1). There was palpable stone in the common bile duct. The common bile duct was explored and the stone was removed. Choledocoscopy was performed intraoperatively assured normal path and T tube was inserted. Postoperative cholangiogram was normal (Filling defect disappeared after flushing with normal saline, which was air). Postoperative period was uneventful (Figure 2).

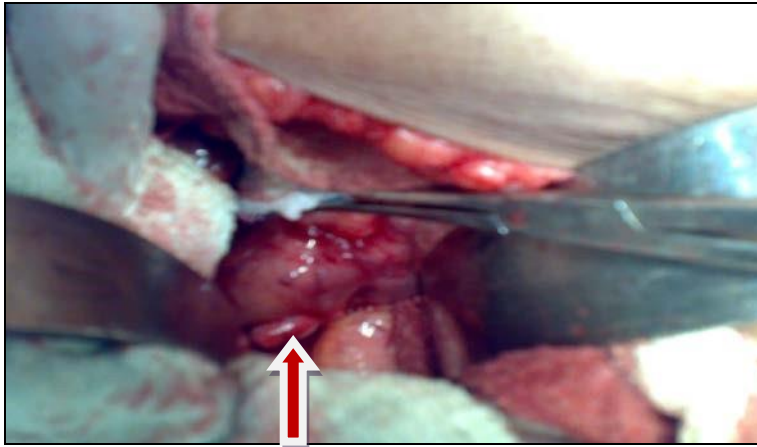


Figure 1: Intraoperative findings: absent gall bladder and only bud -like structure.

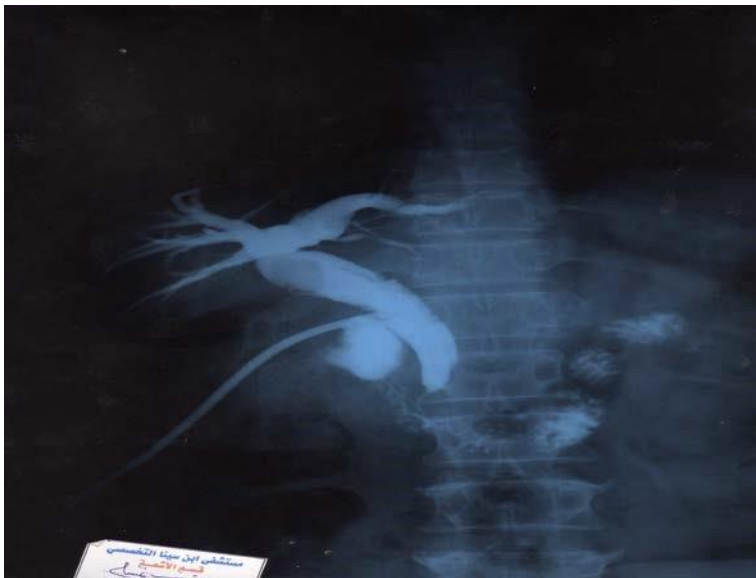

Figure 2: Intraoperative Cholangiogram

Discussion:

The gall bladder develops from the caudal part of the hepatic diverticulum in the fourth week of intrauterine life. Isolated gall bladder agenesis result when this cystic bud doesn't develop. Isolated gallbladder agenesis occur in approximately 0.02% of live birth .The Female: Male incidence is equal in postmortem studies and 3:1 in clinical studies, probably because diagnosis usually occurs at laprotomy of cholelithesis which is more common in women ⁽²⁾ and this was the indication of surgery (cholecystectomy and CBD exploration) following failure of ERCP . In cases reported in the literature, Intraoperative cholangiogram is felt to be essential to exclude or confirm the presence of common bile duct stones and to complete the diagnosis. In our case, it was done for two purposes: (1) to exclude intrahepatic gall

EDITORIAL

bladder and (2) to visualize the biliary system. Several authors recommend routine common bile duct exploration when its diameter is increased or a common bile duct stone has been found^{3, 4, 5}. The investigation of patients with absent gall bladder can be very difficult. If agenesis of the gall bladder is suspected preoperatively by ultrasound stating failure of visualization, further investigations in the form of MRCP and CT scan should be done to confirm the agenesis. If agenesis is confirmed the treatment is non-operative in the form of antispasmodics and endoscopic sphincterectomy. In this case, ultrasound scanning is usually inconclusive and further noninvasive tests should be performed to establish the diagnosis and prevent an unnecessary operation. In addition, the preoperative MRCP images (which were reviewed intraoperatively) were of good quality and we could not identify any filling defect suggesting ductal stones.^{7,8}

Finally absent gall bladder is a bothering abdominal rarity, which is difficult to diagnose preoperatively, because confirmation of clinical calculus cholecystitis is mainly by abdominal ultrasound which is an operator dependent technique, but if you decide to explore it's better to follow the rule (any biliary anomaly you must do intraoperative cholangiogram if possible).

References:

1. Wilson JE, Deitrick JE. Agnesis of the gallbladder: case report and familial investigation. *Surgery*. 1986;99(1):106–109.
2. Blechschmidt CM. Agnesis of the gallbladder—borderline-case of normality? *Anatomischer Anzeiger*. 1982;151(3):281–285.
3. Bennion RS, Thompson JE, Jr., Tompkins RK. Agnesis of the gallbladder without extrahepatic biliary atresia. *Archives of Surgery*. 1988;123(10):1257–1260.
4. Watemberg S, Rahmani H, Avrahami R, Nudelman IL, Deutsch AA. Agnesis of the gallbladder found at laparoscopy for cholecystectomy: an unpleasant surprise. *American Journal of Gastroenterology*. 1995;90(6):1020–1021.
5. Frey C, Bizer L, Ernst C. Agnesis of the gallbladder. *American Journal of Surgery*. 1967;114(6):917–926.
6. Azmat N, Francis KR, Mandava N, Pizzi WF. Agnesis of the gallbladder revisited laparoscopically. *American Journal of Gastroenterology*. 1993;88(8):1269–1270.
7. Hernández JL, Vicente F, Fakh A, Gómez Portilla A, Voltas J, Zornoza G. Vesicular agnesis. Report of 2 cases. *Revista Espanola de las Enfermedades del Aparato Digestivo*. 1985;68(2):166–168.
8. Jackson RJ, McClellan D. Agnesis of the gallbladder. A cause of false-positive ultrasonography. *American Surgeon*. 1989;55(1):36–40.