

EDITORIAL

Naso-Maxillary extramedullary plasmacytoma: A case report

Nazik E Abdullah¹, Mona A A.Raheem², E M Elamin³, Ameera A M Adam⁴,
K M Hamad⁵, Tarig A Hamad⁶ and A M E Hassan⁷

1. FRCSI, DML, Assistant professor, Depart. of Surgery, Faculty of Medicine, University of Khartoum, Sudan
 2. MD, Assistant professor, Faculty of Medicine, Dept. of ENT, Alneleen University, Sudan
 3. Dean of Faculty of Laboratory Sciences (PhD IEND), AL Azhari University, Sudan
 4. PhD student, Immunology section, Institute of Endemic Diseases, University of Khartoum,
 5. Ass. Prof of Oncology (FFRCSI, DMRT, DSN), Faculty of Medicine, University of Khartoum,
 6. ENT Specialist at ENT-Khartoum Teaching Hospital.
 7. Emeritus Professor of Pathology .FRCP, FRCPATH, PhD, DSc. Institute of Endemic Diseases, University of Khartoum.
- Correspondence:** Nazik Elfadil Abdullah, FRCSI, DML. Assistant professor, Department of Surgery, Faculty of Medicine, University of Khartoum, Tel: +249 912161944. Fax +24911 779712 P.O.Box 102 Nazikfad1223@yahoo.co.uk

Abstract:

We report an early case of extramedullary, right maxillary sinus and nasal, plasmacytoma. The patient was a 27 years old female who presented with nasal bleeding and a nasal mass. Imaging studies showed opacities in the nasal cavity and the maxillary sinus but there was no bone involvement. A biopsy from the nasal mass showed a plasmacytoma. She was investigated to rule out systemic disease. The investigations included; serum electrophoresis, urine analysis for Bence Jones proteins, bone marrow aspirates study and radiological skeletal survey. The results of all investigations were negative. After complete excision of the tumour endoscopically the patient was treated with adjuvant radiotherapy. She remained well, without recurrence or spread of the tumour at 4 years follow up. CTscans pre and postoperatively as well as H&E and Immunohistochemistry slides are presented. To our knowledge, this is the first case to be reported in Sudan.

Introduction:

Plasmacytomas are discrete neoplasms composed of monoclonal plasma cells in either bone or soft tissue. Plasmacytomas differ from multiple myeloma in which the lesions are disseminated in the skeletal system and is associated with myeloma protein in the blood and urine ^(1, 2, 3). In a simplified description plasmacytoma is divided into two groups: Plasmacytoma of the skeletal system (SBP) and Extramedullary plasmacytoma (EMP). Extramedullary plasmacytoma (EMP) is uncommon and represents about 3% of all plasma cell neoplasms. Almost 90% of EMP occurs in the head and neck area in the upper respiratory tract. The gastrointestinal tract is a very rare site of involvement of this neoplasm. ^(1, 2, 3) EMP accounts for 1% of all head and neck malignancies⁽⁴⁾. Predilection sites are: the naso-maxillary region, nasopharynx, oropharynx and larynx, in that order of frequency ⁽⁵⁾. Males are affected more than females and around 95% of cases are above 40 years⁽⁶⁾.

Diagnostic criteria for extramedullary plasmacytoma (EMP) are ⁽⁷⁾:

- Tissue biopsy showing monoclonal plasma cell histology.
- Bone marrow plasma cell infiltration not exceeding 5% of all nucleated cells.
- Absence of osteolytic bone lesions or other tissue involvement (no evidence of myeloma).
- Absence of hypercalcemia or renal failure.
- Low serum M protein concentration, if present.

EDITORIAL

Case presentation:

A 27 year old lady presented to the ENT Clinic at Soba University Hospital with recurrent right side epistaxis for 7 months and right nasal obstruction of 3 months duration. Nasal endoscopy revealed dark-red fleshy mass in the right nasal cavity; the cervical lymph nodes were not palpable and there was no evidence of cranial nerves involvement. CT scan showed opaque right nasal cavity and partially opaque right maxillary sinus with conserved bone outlines and no evidence of bone erosion (Figure 1 A & B).

She was further investigated to rule out systemic disease. The investigations included; serum electrophoresis, urine analysis for Bence Jones proteins, bone marrow aspirates study and plain radiological skeletal survey. The results of all investigations were negative.

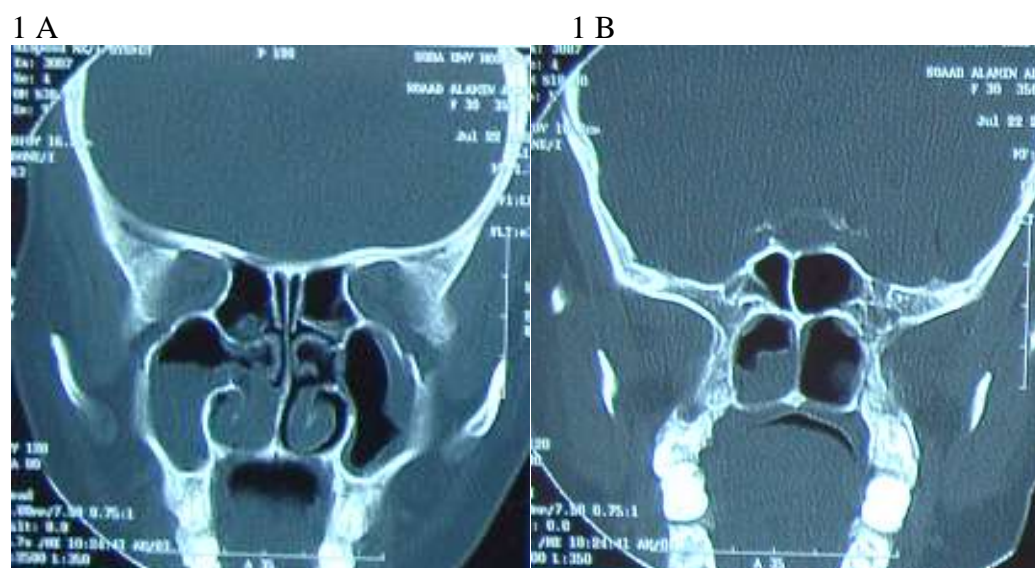


Figure (1) A and B: Coronal views of CT scan of the nose and sinuses

The patient underwent excisional biopsy via endoscopic approach under general anesthesia. The mass was completely excised with removal of surrounding periosteum and the inferior turbinate, the specimen was sent for histopathology. Sections of the mass showed sheets of mature plasma cells in a scanty stroma. Few small lymphocytes were scattered in the lesion (Figure 2). Immunohistochemistry study of the mass was positive for IgG and negative for IgA, IgM, CD20 and CD3 (Figure 3).

A diagnosis of plasmacytoma was made. Postoperatively the patient was treated with external beam radiation as adjuvant therapy at the radiation and Isotope Centre-Khartoum. Follow up of the patient revealed no evidence of local recurrence or systemic disease four years following the initial diagnosis (Figure4).

Discussion:

Extramedullary plasmacytoma is a rare pathology in the head and neck region. It constitutes 4% of all nonepithelial tumors of the nose, paranasal sinuses and nasopharynx ⁽⁸⁾. It should be included in the differential diagnosis of patients who present with nasal bleeding due to a mass involving this area.

EDITORIAL

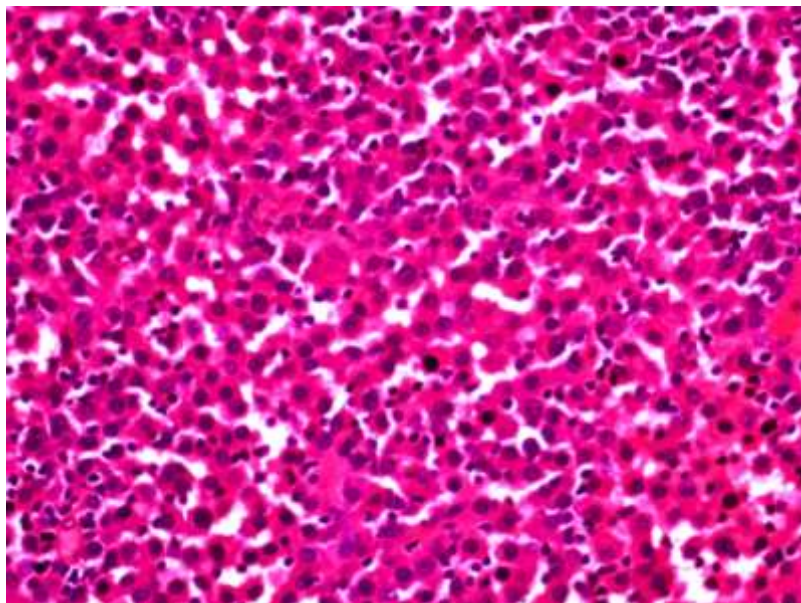


Figure (2): Specimen histopathology: Haematoxylin and Eosin section X40 magnification




Figure (3): Immunohistochemistry slides

EDITORIAL

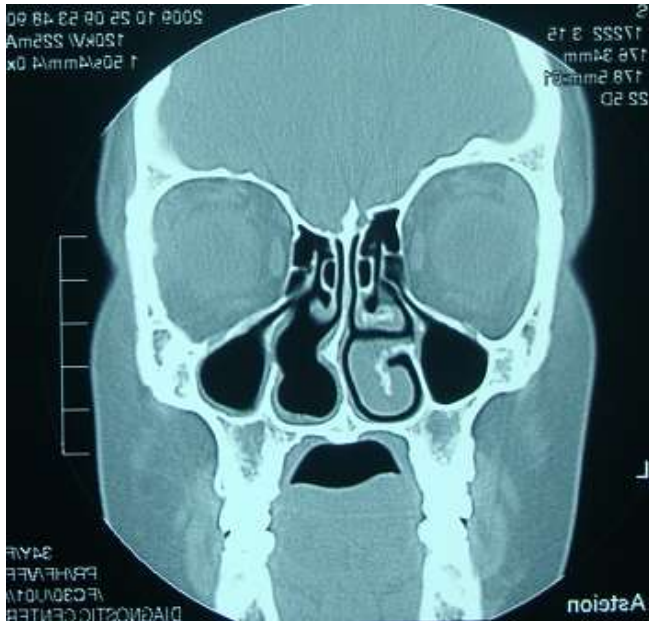


Figure (4): CT scan of the nose and sinuses, four years after treatment

The peak age of extramedullary plasmacytoma patients ranges between 60 to 70 years⁽⁹⁾. Cases in younger age groups are uncommon. The youngest patient with plasmacytoma involving the maxillary sinus was a 10 years old female⁽¹⁰⁾. The case presented here is younger than the average age by 38 years.

The radiology of this case showed partial opacity of right maxillary sinus and right nasal cavity with no bone erosion. This, along with absence of tumour at other sites including the bone marrow, shows that the tumour in our patient satisfies the criteria for diagnosis of extramedullary plasmacytoma. To our knowledge, this is the first case to be reported in Sudan.

The fact that EMP can be associated with or progresses to multiple myeloma necessitates other investigations to exclude systemic disease. Follow up should continue for at least 10 years as progression to multiple myeloma occurs in up to 36% of cases⁽¹¹⁾.

Although EMP is radiosensitive, the combination of surgery and radiation therapy is advocated by many authors^(12, 13). In the present case, endoscopic surgery was satisfactory, nevertheless adjuvant radiotherapy was offered to the patient to eliminate a possible microscopic residue. Nodal involvement and a tumour exceeding 5 cm indicate poor prognosis⁽¹⁴⁾. Good prognosis is expected for the present case as the tumour is small, localised and is not associated with nodal involvement. These are the three important prognostic factors.

Conclusion:

Extramedullary plasmacytoma is a localised form of plasmacytoma. The present case is unique in that she is a female and being 38 years younger than the average age for the tumour. Treatment of EMP includes surgery and radiotherapy. It carries good prognosis if diagnosed at an early stage. Follow up is of paramount importance in order to detect local recurrence and/or distant metastasis.

EDITORIAL

Acknowledgement:

We would like to acknowledge the medical staff of Al-Zahrawi Medical laboratory for their cooperation in preparation of the histopathology and immunohistochemistry sections in this manuscript.

References:

1. Bataille R, Sany J. Solitary myeloma: clinical and prognostic features of a review of 114 cases. *Cancer*. Aug 1 1981;48(3):845-51.
2. Corwin J, Lindberg RD. Solitary plasmacytoma of bone vs. extramedullary plasmacytoma and their relationship to multiple myeloma. *Cancer* Mar 1979; 43(3): 1007-13.
3. McLain RF, Weinstein JN. Solitary plasmacytomas of the spine: a review of 84 cases. *J Spinal Disord*. Jun 1989;2(2):69-74.
4. Webb HE, Harrison EG, Masson JK, Remine WH. Solitary extramedullary myeloma (plasmacytoma) of the upper part of the respiratory tract and oropharynx. *Cancer* 1962;15:1142-55.
5. Alexiou C, Kau RJ, Dietzfelbinger H, et al. Extramedullary plasmacytoma: Tumor occurrence and therapeutic concepts. *Cancer* 1999;85:2305-14.
6. Kapadia SB, Desai U, Cheng VS. Extramedullary plasmacytoma of the head and neck. A clinicopathologic study of 20 cases. *Medicine* 1982;61:317-29.
7. Galieni P, Cavo M, Pulsoni A, et al. Clinical outcome of extramedullary plasmacytoma. *Haematologica*. Jan 2000;85:47-51.
8. Fu YS, Perzin KH. Nonepithelial tumors of the nasal cavity, paranasal sinuses and nasopharynx. A clinicopathologic study. IX. Plasmacytomas. *Cancer* 1978;42:2399-2406.
9. Megat Shiraz M A R, Jong Y H, Primuharsa Putra S H A. Extramedullary plasmacytoma in the maxillary sinus: *Singapore Med J* 2008; 49:310-311.8.
10. A. Jaswal, G. Biswas, B. Sikder, A. Das, T. Nandi. Extramedullary plasmacytoma of maxillary sinus in 10-year-old girl: A rare presentation: *International Journal of Pediatric Otorhinolaryngology Extra* September 2008;4: 143-146.
11. Holland J, Trenker DA, Wasserman TH, Fineberg B. Plasmacytoma. Treatment results and conversion to myeloma. *Cancer* 1992;69: 1513-17.
12. Hu K, Yahalom J. Radiotherapy in the management of plasma cell tumors. *Oncology* 2000;14: 111-115.
13. Windfuhr JP, Ott G. Extramedullary plasmacytoma manifesting as a palpable mass in the nasal cavity. *Ear Nose Throat J* 2002;81: 110-14.
14. Straetmans J and Stokroos R. Extramedullary plasmacytomas in the head and neck region: *European Archives of Oto-Rhino-Laryngology* 2008;265:, 1417-1423.