

EDITORIAL

Medical Treatment of Cystoid Macular Edema with Topical Steroids and Topical Non-Steroidal Anti-Inflammatory Drugs

Mahmoud A. Salim¹, Rawya A. Diab², Sana Ahmed², Zuhail Alhassan²

1- MD, Assisstant professor. Ophthalmology Department, Faculty of Medicine; University of Gezira.

2- Ophthalmology Resident; SMSB.

Abstract:

Aim: To provide knowledge that topical steroids and topical non-steroidal antiinflammatory drugs "NSAIDs"; can cure cystoid macular edema "CME"; which is currently mostly treated by invasive procedures "i.e. intravitreal steroids and anti VEGF, laser and vitrectomy".

Introduction: Through many years ever since the CME has been discovered by Irvin, invasive interventions were regarded as the most effective curative modalities of treatment. Recently it was proved that there is an inflammatory reaction in the process of CME formation, based on that evidence many studies started aiming at evaluating the role of anti-inflammatory agents in the treatment of CME.

Case presentation: A 60 years old gentleman presented with deterioration of vision in his right eye over 45 days, he is on antiglaucoma medications and has undergone a glaucoma surgery two years back, there were no any associated systemic symptoms or diseases. On examination: the left eye was diagnosed as end stage glaucoma and so it was excluded from the examination; on examination of the right eye: best corrected visual acuity was 6/36; intra ocular pressure "IOP" 10 mmHg, dilated fundus examination: Optic disc: glaucomatous atrophy, Vessels: attenuated arterial system and congested venous system, Macula: dull with irregular slit lamp light appearance indicating microcysts formation; and Periphery: was non informative, Ocular Coherent Tomography "OCT": showed marked increased thickness of the retinal layers with cysts formation at the macular area. Accordingly the patient was diagnosed as cystoid macular edema and hence the plan was to put him on topical steroids and topical NSAIDs eye drops qid, a regular follow up and measurement of IOP.

Results: OCT repeated after a month and there were no obvious changes, four months later OCT showed a remarkable improvement; i.e. the thickness is much lesser, another OCT after a further month showed complete resolution of the edema, and best corrected visual acuity was 6/24.

Discussion and Conclusion: CME is in part an inflammatory condition; so it could possibly be treated with anti-inflammatory agents, such as topical steroids and NSAIDs, as it is evident in this case CME can be totally cured without the need of invasive procedures.

Keywords: CME, Topical NSAIDs, OCT, IOP, slit lamp light, anti VEGF

Introduction:

Cystoid macular edema arises due to the breakdown of the blood-retinal barrier causing accumulation of fluid within the retina, specifically between the inner nuclear and outer plexiform layers, resulting in a "flower petal" appearance¹. The exact etiology is unknown, most often it follows a previous ocular surgery "glaucoma surgery in our case"; other risk factors may include: retinal vascular disease, inflammation, drug-induced etc. Pathogenesis of CME is still obscure, it is perhaps a multifactorial, but most of the investigators agree that the major etiological factor especially in post operative CME is inflammation including

EDITORIAL

endogenous prostaglandin and other medical mediators, other factors include vitreous traction, endophthalmitis, and vascular instability etc². A patient with CME may be asymptomatic or may complain of decreased vision, a positive central scotoma or metamorphopsia, clinically it is best detected by binocular slit lamp examination with the Goldmann fundus contact lens or Hruby lens; a loss of foveal reflex and depression and appearance of yellowish spot, rosette pattern can also be noticed³, Amsler grid is also helpful; then a final diagnosis can be reached by requesting OCT and/or Fluorescein angiography. Regarding the treatment, there are many options; in this case report we are concentrating on the outcome of topical NSAIDs and steroids. **Topical NSAIDs** inhibit the enzyme cyclooxygenase, which is required for the production of the prostaglandins as a degradation product of arachidonic acid. There is evidence that some NSAIDs may also act on other mediators; it can also be used as a prophylactic modality. **Topical Steroids** also inhibit the production of prostaglandins, but at a higher level in the biochemical pathway, by inhibiting the enzyme phospholipase A2, which catalyses the conversion of membrane lipids to arachidonic acid. By this process, steroids inhibit the formation of both prostaglandins and leukotrienes, locally their vasoconstrictive properties decrease intracellular and extracellular edema, suppress macrophage activity, and decrease lymphokine production. Clinical experience has shown that pseudophakic CME usually responds well to local therapy of steroids and NSAIDs and/or in association with systemic acetazolamide⁴.

Literature review

Numerous studies have reported NSAIDs' efficacy in the prophylaxis of pseudophakic CME. A meta-analysis by Luca Rosetti, MD, and colleagues in 1998 concluded topical NSAID administration was beneficial in lowering the incidence of angiographically and clinically diagnosed pseudophakic CME. A randomized, controlled trial examined topical indomethacin for pseudophakic CME prophylaxis and treatment. The study of 189 eyes reported a pseudophakic CME incidence of 0 percent for eyes receiving preoperative and postoperative indomethacin, 15 percent for eyes receiving postoperative indomethacin only, and 33 percent for controls. Another large multicenter RCT reported improvement in visual acuity in the treatment of chronic aphakic and pseudophakic CME using 0.5% ketorolac (Acular, Allergan). Limited data is known about the long-term effects (>one year) of NSAIDs on pseudophakic CME⁵. It does appear that combination therapy with topical NSAID and corticosteroid may be superior to either individual therapy. A small, randomized control trial in 2000 compared topical ketorolac to topical prednisolone to combination therapy for the treatment of pseudophakic CME. Average improvement in Snellen visual acuity over three months was 1.6 lines in the ketorolac group, 1.1 lines in the prednisolone group and 3.8 lines in the combination group. Perhaps a synergistic effect is observed with combination therapy, although more studies are needed⁵.

Discussion:

No doubt that CME constitutes a great challenge, as many factors can lead to CME; treatment options vary. Therapeutic interventions are based on the proposed pathogenesis of edema, mainly inflammation and vitreous traction⁵. For most retina specialists, the current primary treatment modality for CME consists of both a corticosteroid and an NSAID, administered topically. Prior to the development of NSAIDs that have improved posterior segment penetration, many retina specialists did not use topical NSAIDs. Treatment strategies have changed with the evolution of the currently available NSAIDs that offer better penetration, are effective in treating CME and may have an important role in reducing the incidence of CME. ⁽⁶⁾

EDITORIAL

Name: Salah, Mohammed Elais

ID: 0578

DOB: 1/1/1952

Gender: Male

Doctor:

Exam Date: 11/11/2013

Exam Time: 1:22 PM

Serial Number: 400-12185

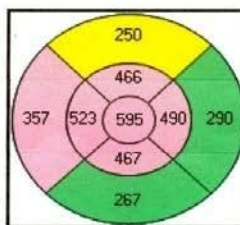
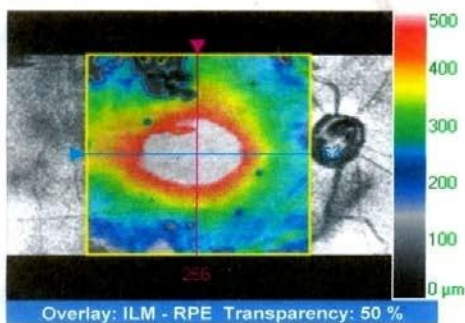
Signal Strength: 3/10

Alsaim Hospital



Macula Thickness : Macular Cube 512x128

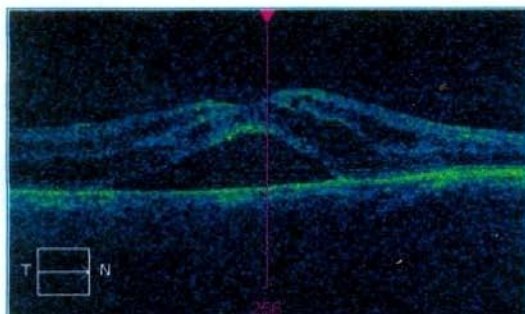
OD OS




ILM-RPE Thickness (µm)



Fovea: 256, 64



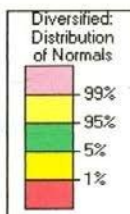
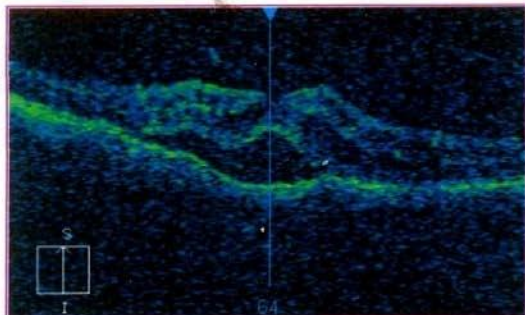
ILM - RPE



ILM



RPE



	Central Subfield Thickness (µm)	Cube Volume (mm³)	Cube Average Thickness (µm)
ILM - RPE	595	11.4	318

Comments

Analysis Edited: 11/11/2013 1:26 PM

Doctor's Signature

SW Ver: 6.0.2.81
 Copyright 2012
 Carl Zeiss Meditec, Inc
 All Rights Reserved
 Page 1 of 1

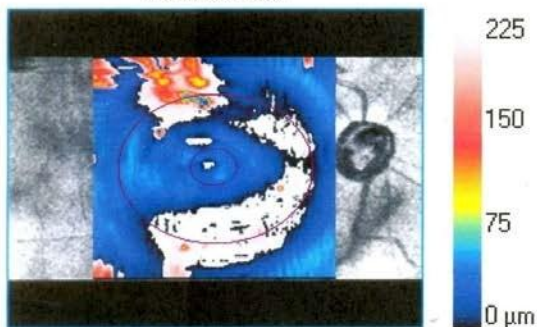
EDITORIAL

Name: Salah, Mohammed Elais OD
 ID: 0578 Exam Date: 11/11/2013 Alsaim Hospital
 DOB: 1/1/1952 Exam Time: 1:22 PM
 Gender: Male Serial Number: 400-12185
 Doctor: Signal Strength: 3/10



Ganglion Cell OU Analysis: Macular Cube 512x128 OD OS

OD Thickness Map

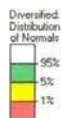
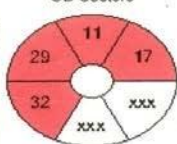


Fovea: 256, 64

OD Deviation Map

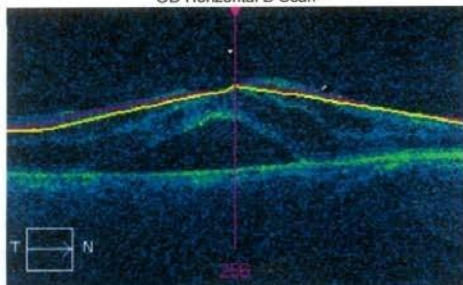


OD Sectors



	OD μm	OS μm
Average GCL + IPL Thickness	14	X
Minimum GCL + IPL Thickness	8	X

OD Horizontal B-Scan

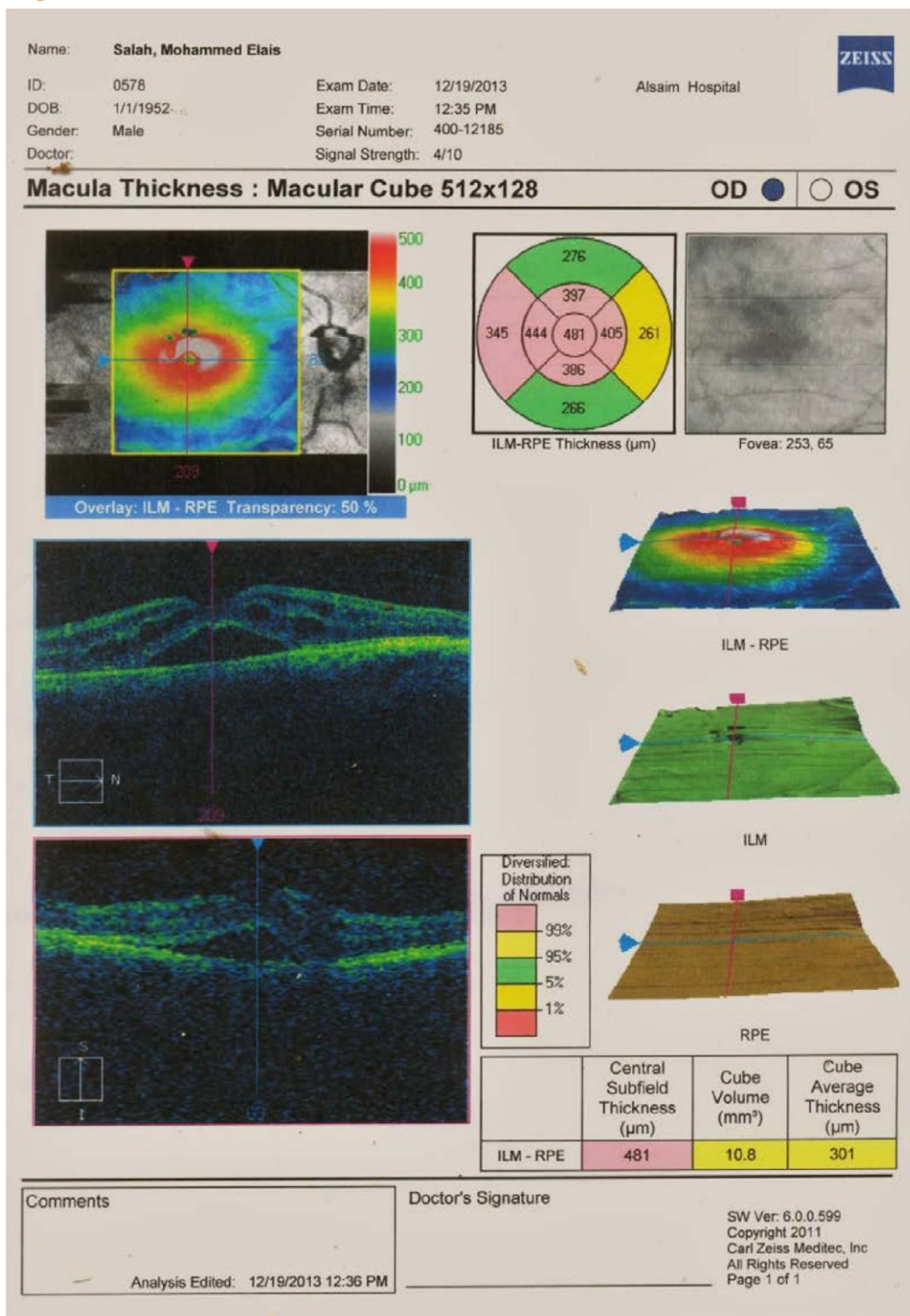


Comments
 Analysis Edited: 11/11/2013 1:26 PM

Doctor's Signature

SW Ver: 6.0.2.81
 Copyright 2012
 Carl Zeiss Meditec, Inc
 All Rights Reserved
 Page 1 of 1

EDITORIAL



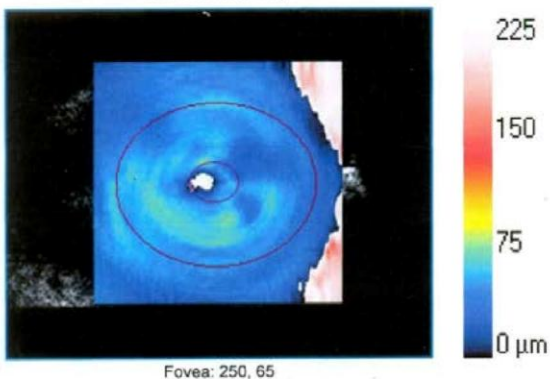
EDIT

Name: **Salah, Mohammed Elais** OD
 ID: 0578 Exam Date: 3/13/2014 Alsaim Hospital
 DOB: 1/1/1952 Exam Time: 10:43 AM
 Gender: Male Serial Number: 400-12185
 Doctor: Signal Strength: 5/10




Ganglion Cell OU Analysis: Macular Cube 512x128 OD OS

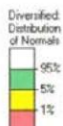
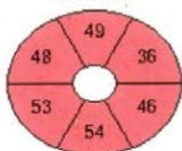
OD Thickness Map



OD Deviation Map

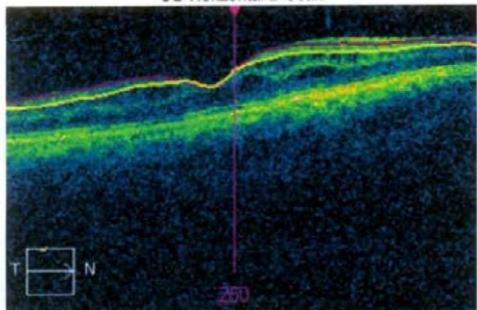


OD Sectors



	OD μm	OS μm
Average GCL + IPL Thickness	48	X
Minimum GCL + IPL Thickness	30	X

OD Horizontal B-Scan



Comments

Doctor's Signature

Analysis Edited: 3/13/2014 10:47 AM

SW Ver: 6.0.0.599
 Copyright 2011
 Carl Zeiss Meditec, Inc
 All Rights Reserved
 Page 1 of 1

Name: Salah, Mohammed Elais

ID: 0578

Exam Date: 3/13/2014

Alsaim Hospital

DOB: 1/1/1952

Exam Time: 10:43 AM

Gender: Male

Serial Number: 400-12185

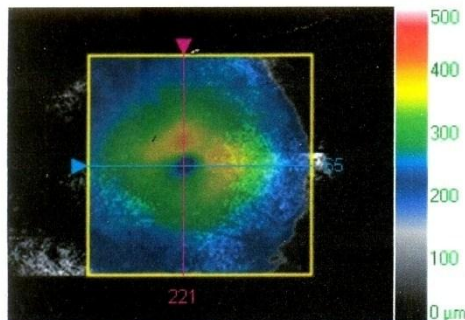
Doctor:

Signal Strength: 5/10

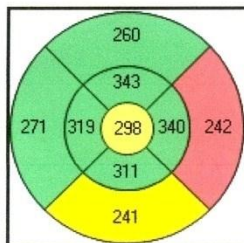


Macula Thickness : Macular Cube 512x128

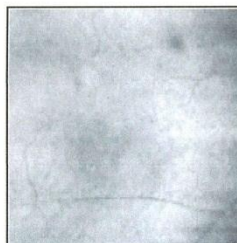
OD OS




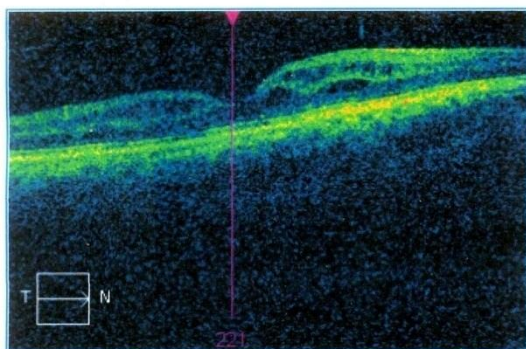
Overlay: ILM - RPE Transparency: 50 %




ILM-RPE Thickness (µm)




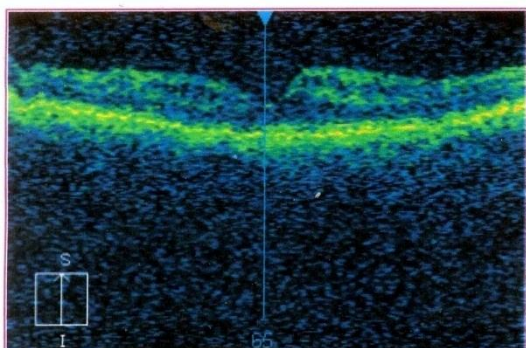
Fovea: 250, 65



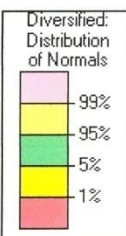
ILM - RPE



ILM



RPE



	Central Subfield Thickness (µm)	Cube Volume (mm ³)	Cube Average Thickness (µm)
ILM - RPE	298	8.7	245

Comments

Analysis Edited: 3/13/2014 10:47 AM

Doctor's Signature

SW Ver: 6.0.0.599
Copyright 2011
Carl Zeiss Meditec, Inc
All Rights Reserved
Page 1 of 1

Name: **Salah, Mohammed Elais**

ID: 0578

DOB: 1/1/1952

Gender: Male

Doctor:

Exam Date: 4/24/2014

Exam Time: 11:35 AM

Serial Number: 400-12185

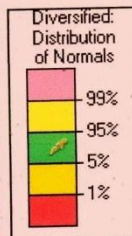


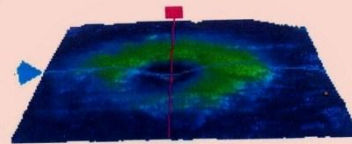
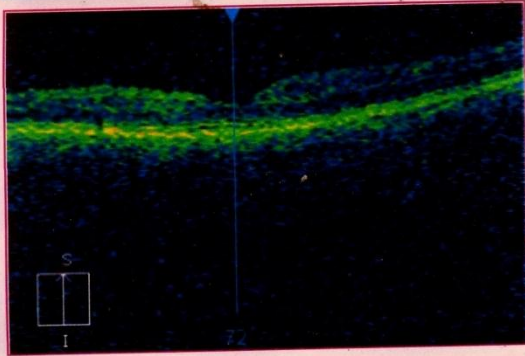
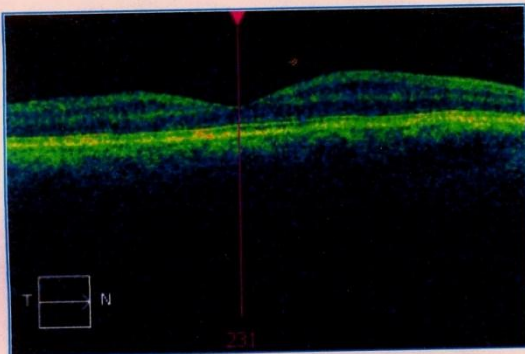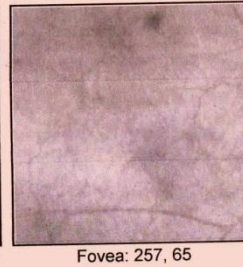
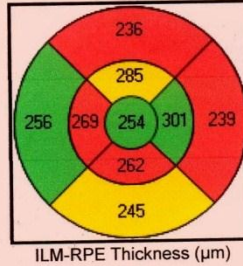
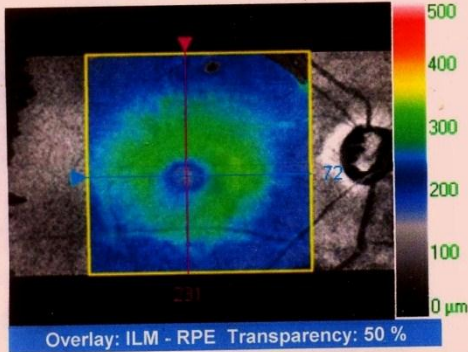
Signal Strength: 5/10

Alsaim Hospital



Macula Thickness : Macular Cube 512x128

OD OS



	Central Subfield Thickness (µm)	Cube Volume (mm³)	Cube Average Thickness (µm)
ILM - RPE	254	8.6	241

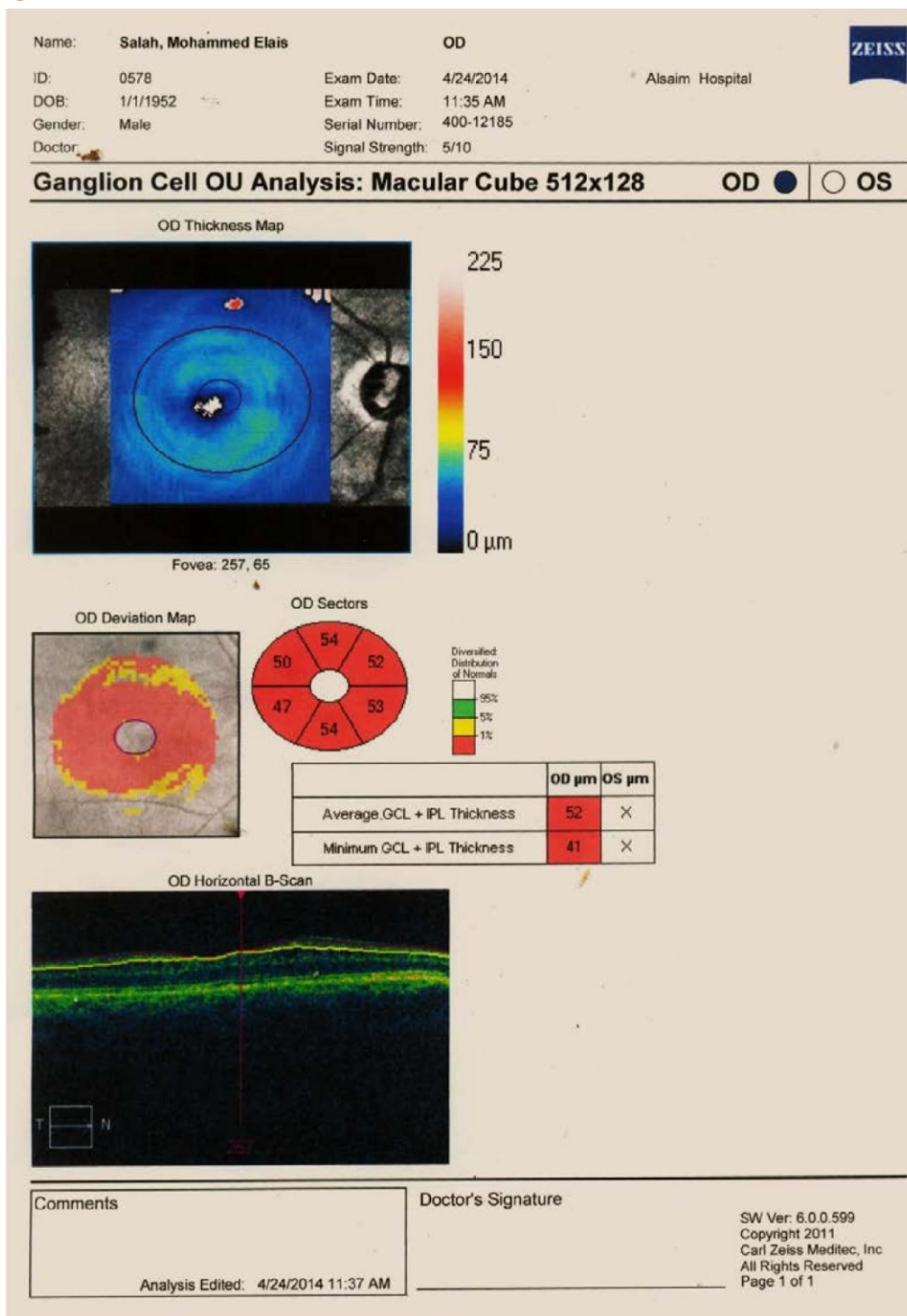
Comments

Analysis Edited: 4/24/2014 11:37 AM

Doctor's Signature

SW Ver: 6.0.0.599
 Copyright 2011
 Carl Zeiss Meditec, Inc
 All Rights Reserved
 Page 1 of 1

EDITORIAL



Conclusion:

CME is still an area of ongoing research and further exploration both in regard to its pathogenesis and management. So far there is no standardized regimen in treating CME. The difficulty is because that most of the CME cases resolve spontaneously in addition to the fact that there are no experimental models. Most of the lab animals have no macula and those which do have, their macula are resistant to CME, but as it was clearly proved in this case and from the literature reviews, and relying on that there is an inflammatory factor in CME, there are promising results supporting that topical medications "Steroids & NSAIDs" can lead to satisfying outcomes i.e. complete resolution of the CME, and visual acuity improvement, and they may even have a prophylactic role as well.

EDITORIAL

Summary:

We recommend that it is better to start treating CME patient by topical steroids and NSAIDs eye drop with regular follow up before commencing invasive interventions. Though most of the CME patients can benefit from this protocol, some do need other modalities. So every patient has to be thoroughly assessed, and then the choice of treatment has to be tailored accordingly. We encourage more researches to be done in this subject, and in finding measurements to prevent its occurrence.

References:

1. <http://www.hindawi.com/journals/criopm/2012/530128/>
2. <http://www.ncbi.nlm.nih.gov/pmc/articles/PMC1298410/?page=12>
3. <http://www.ncbi.nlm.nih.gov/pmc/articles/PMC1298410/?page=6>
4. <http://www.ncbi.nlm.nih.gov/pubmed/10896343/>
5. http://www.revophth.com/content/d/retinal_insider/c/46967/
6. <http://www.healio.com/ophthalmology/cataract-surgery/news/online/%7Ba232eb9c7013-491b-8ef0-4b1f7825ff82%7D/prevention-and-treatment-of-cystoid-macularedema>