

Endobronchial Lipoma: A Case Report

SalahEldinM E H¹, Ismail Murad² and Gumaa Aboul Nasr Khalil³

1. MD.MRCSEng.FEBCTS. Associate professor, Dept. Of Surgery, Faculty of Medicine, University of Gezira. Wad-Medani Cardiac Center
2. MD, Giza chest hospital.
3. Giza chest hospital.

Corospondence: SalahEldinMohamed Elmustafa Hassan

Introduction:

Benign tumors of the lung and endobronchial tree are uncommon. Endobronchial lipoma is an extremely rare benign tumor, with an incidence ranging from only 0.1 to 0.5% of all lung tumors⁽¹⁾. Endobronchial lipomas originate from the fat cells located in the peribronchial and occasionally the sub mucosal tissue of main bronchi⁽²⁾. These tumors of the large bronchi occur in middle-aged men. The symptoms are those of obstructive pneumonitis mimicking bronchogenic carcinoma, and the result of delayed therapy may be bronchiectasis. Treatment includes local resection through a bronchoscope or a bronchotomy incision, or removal, if necessary, of the obstructed lobe or lung at thoracotomy. Smoking may be important in the pathogenesis of this tumor.

Case:

A 37-year-old man presented with shortness of breath for few weeks and was treated as a case of asthma. On examination, he had stridor. X-ray showed unilateral inflation of the left lung. The spirometry trace indicated obstruction of the large airways. Chest computed tomography (CT) scan demonstrated a soft tissue density mass in the left main bronchus (Figure 1) which raises the possibility of a benign intrabronchial mass. Flexible bronchoscope showed well circumscribed rounded mass completely filling the lumen of the left main bronchus.. Surgical excision of the mass and subsequent histological examination confirmed the diagnosis of endobronchial lipoma.

The patient showed no post operative complications and was discharged in 8 days. He had an uneventful follow up

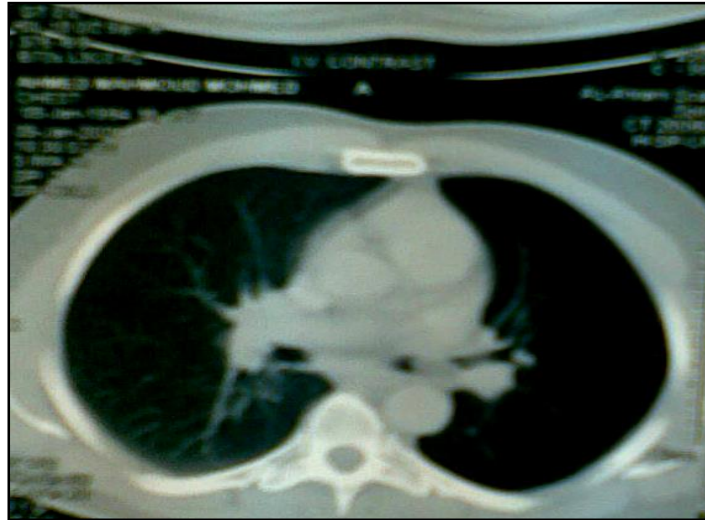


Figure (1): CT scan: The mass inside the left main bronchus

Discussion:

Most tumors of the tracheobronchial tree are malignant. Benign pulmonary tumors are rare entities, and among them lipomas are the most uncommon. Endothoracic lipomas are categorized into 5 groups: endobronchial, parenchymatous, pleural, mediastinal and cardiac⁽³⁾. Due to mechanical obstruction of the bronchus, endobronchial lipomas cause symptoms. Some investigators claim that smoking and obesity are significant risk factors for endobronchial lipoma⁽⁴⁾.

The CT scan findings of lipoma, homogeneous mass with fat density and no enhancing contrast are diagnostic. CT scan is valuable in localizing the origin and extent of the tumor.

In the literature, two-thirds of the lipomas occurred on the right side of the tracheobronchial tree, and most were located in the first three subdivisions of the tracheobronchial tree⁽⁵⁾. In this patient endobronchial lipoma was located in the left main bronchus and filled the lumen completely.

When the spirometry indicates obstruction of the large airways, the patient should be evaluated with CT scan and flexible bronchoscopy. These tumors can be managed by bronchoscopy; if bronchoscopic therapy is not possible, it should be considered for surgical resection before the tumor leads to irreversible bronchiectasis.

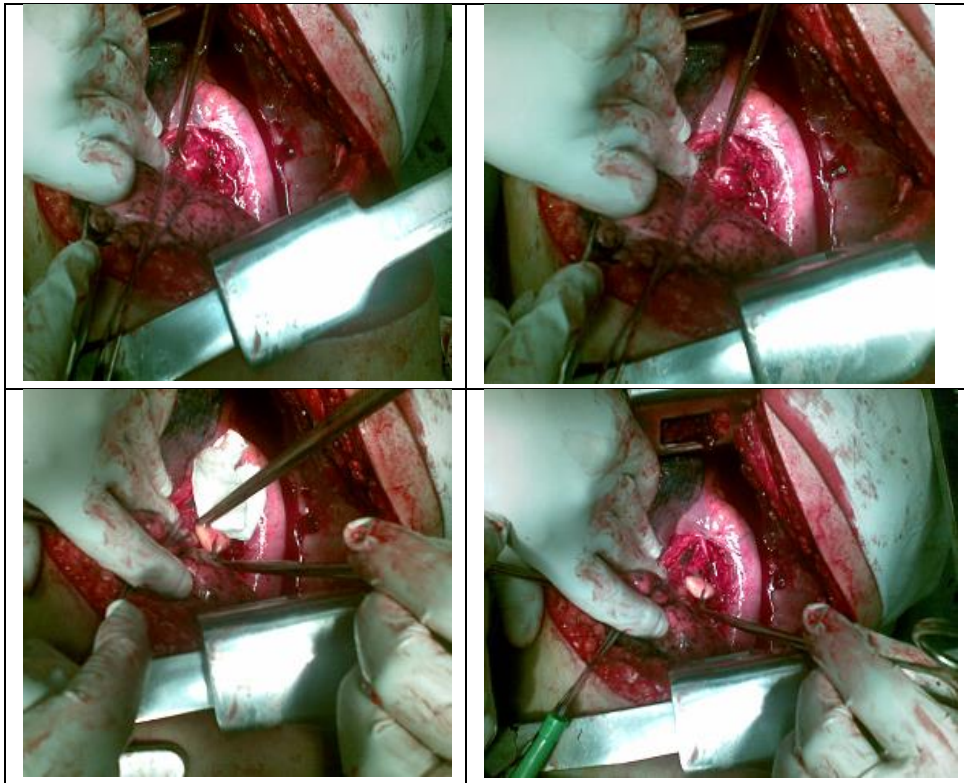


Figure (2): The excision process

Bronchoscopic resection should be considered as the first choice of treatment for endobronchial lipoma; however, surgical therapy is indicated for patients who show the possibility of a complicated malignant tumor, who have destructive peripheral lung disease, who have extrabronchial growth, or who may have technical difficulties during the bronchoscopic procedure.

A posterolateral left thoracotomy was done and the left main bronchus identified below the aortic arch. After slinging, a 2cm bronchotomy was done and the lipoma was easily delivered and excised. Bronchotomy closed with interrupted 3\0 Maxon®. (Figure 2). The patient showed no post operative complications and was discharged in 8 days. He had an uneventful follow up.

EDITORIAL

References:

1. *Jensen MS, Petersen AH. Bronchial lipoma. Scand Thorac Cardiovasc Surg. 1970;4:131–134.*
2. *Farsad G, Makoui C. Endobronchial lipoma. Am Surg. 1981;47:236–238.*
3. *Politis J, Funahashi A, Gehlsen JA, DeCock D, Stengel BF, Choi H. Intrathoracic lipomas: report of three cases and review of the literature with emphasis on endobronchial lipoma. J Thorac Cardiovasc Surg. 1979;77:550–556.*
4. *Schraufnagel DE, Morin JE, Wang NS. Endobronchial lipoma. Chest. 1979;75:97–99*