

EDITORIAL

Management of Undescended Testis in Gezira National Center for Pediatric Surgery (2009–2011)

Omer Osman Eltayeb ¹, Faisal Abdalgalil Nugd ², Osman Taha Mohammed ³ and Diaa eldinn Yaseen Salman ⁴

1. MBBS, Registrar of General Surgery, Sudan Medical Specialization Board-
2. MD, Associate professor of pediatric surgery, Faculty of Medicine, University of Gezira
3. FRCSI, Professor of pediatric surgery, Faculty of Medicine, University of Gezira
4. MD, Assistant professor of surgery, Faculty of Medicine, Gezira university

Correspondence: Omer O E Ahmed, Tel +249-912412711, e-mail: aboly98@hotmail.com

Abstract:

Background: Undescended Testis (UDT) or Cryptorchidism is the most common genital problem encountered in paediatrics. Untreated UDT/cryptorchidism clearly has deleterious effects on the testis over time. In Gezira National Center for Pediatrics Surgery (GNCPS) UDT\Cryptorchidism had been treated since early 80s. During this period no study was taken to evaluate this condition.

Methods: This is a retro-prospective descriptive study done over a 2 year period from Oct 2009 to Oct 2011 including all patients with UDT operated on in the GNCPS. Patients were evaluated regarding the age at presentation, age at surgery, site of the UDT, location of the testes, investigations done and treatment modality.

Results: A total of 232 children underwent orchidopexy for UDT in GNCPS, 81.5% of those patients were older than 2 years. Bilateral cases were 16.8%. Nonpalpable testes found in 36.6% of cases. Dartos pouch fixation was used in 79.8 % of the cases.

Conclusion: the majority of children with UDT presented at an age older than two year which reflect the delay in diagnosis due to lack of adequate neonatal examination.

ملخص:

خلفية: مرض الخصية المعلقة هو من اكثر الامراض المتعلقة بالجهاز التناسلي شيوعا لدى الاطفال. عدم انزال الخصية المعلقة له اثار وخيمة على الخصية كلما تقدم الزمن. في مركز الجزيرة القومي لجراحة الاطفال يتم علاج الخصية المعلقة بانتظام منذ اوائل الثمانينات ورغم ذلك لم تجرى اي ابحاث لدراسة هذه الحالة.

الطريقة والبحث: هذه الدراسة هي دراسة وصفية لاحقة تم اجراؤها خلال عامين ابتداء من اكتوبر 2009 حتى اكتوبر 2011 جميع المرضى الذين تم اجراء عمليات جراحية لهم لانزال الخصية المعلقة تمت دراستهم من حيث العمر الذي حضر به للمستشفى. العمر الذي اجريت فيه العملية. اتجاه الخصية المعلقة ومكانها. الفحوصات التي اجريت له والعلاج الذي تلقاه.

النتائج: خلال فترة الدراسة 232 طفل تم علاجهم في المركز 81.5% منهم كانت اعمارهم فوق السنتين 16.8% منهم كانت المشكلة بالجانبين و 36.6% منهم لم تكن الخصية محسوسة بالكشف السريري. تم استعمال التثبيت في جراب دارتوس في 79.8% من الحالات.

الخلاصة: ان غالبية الحالات تحضر في عمر اكثر من عامين مما يعكس سلبا على العلاج ويحدث هذا التأخير نتيجة لقلة الكشف على حديثي الولادة.

Key words: Undescended Testis (UDT), Gezira National Center for Pediatrics Surgery Sudan (GNCPS), orchidopexy

Introduction:

Cryptorchidism or undescended testes (UDT) is the most common genital problem encountered in pediatrics. Cryptorchidism literally means hidden or obscure testis and generally refers to an UDT or maldescended testis. Despite more than 100 years of research, many aspects of cryptorchidism are not well defined and remain controversial. Untreated cryptorchidism clearly has deleterious effects on the testis over time. ⁽¹⁾

The structure of medical systems varies throughout the world. For a given medical system there must be guidelines for screening for undescended testes in view of the relatively high frequency. In view of the natural history of descent the ideal is to examine all boys at birth for testicular position. However, at times

EDITORIAL

the scrotal contents, presumably the thick gubernaculum, can be difficult to distinguish from a testis. For this reason it is wise to repeat the examination at a routine baby check at 6 weeks of age. If a testis is found missing then the child should be seen at one year of age. This is an important examination that needs to be performed by a professional trained and experienced doctor or nurse in such examination. Who this will be, depends on the structure of the medical services available and could be a specially trained nurse or a doctor. Either way the team needs to be led by a pediatric surgeon. ^(1, 2)

About 3% of full-term and 30% of premature infant boys are born with at least one UDT, making cryptorchidism the most common birth defect of male genitalia. However, about 80% of cryptorchid testes descend by the first year of life; the majority within three to six months, making the true incidence of cryptorchidism around 1% overall. ⁽¹⁾

About two thirds of cases, without other abnormalities, are unilateral and one third of cases involve both testes. In 90% of cases an UDT can be palpated in the inguinal canal; in a minority the testes are in the abdomen or nonexistent. ⁽²⁾

UDT are associated with reduced fertility, increased risk of testicular germ cell tumors and psychological problems when the boy is grown. UDT are also more susceptible to testicular torsion and infarction and inguinal hernias. To reduce these risks, undescended testes are usually brought into the scrotum in infancy by a surgical procedure called an orchidopexy. ^(3, 4, 5, 6)

Treatment for UDT may include manipulation into the scrotum, hormone therapy and surgery ^(7, 8). Treatment is not recommended until after the age of 1 year ⁽⁹⁾, because in most cases, the testis descends without intervention during this time. ⁽¹⁰⁾

Patients and methods:

This is a descriptive retro-prospective hospital based study done over a 2 years period from Oct 2009 to Oct 2011 including all patients seen in the Gezira National Center for Pediatrics Surgery with undescended testis. Patients were evaluated regarding the age of presentation, age of surgery, site of the problem, location of the testes, investigations done, and treatment modality. Patients were assessed by pediatric surgeon who set the plan for their management.

When a decision of surgical management is considered, patient is booked on operative list and prepared for surgery, usually they come one day before surgery to be examined for fitness for surgery. In GNCPS we do either open approach through inguinal incision or laparoscopic approach.

All patients were seen after 2 weeks and then 6 months following the surgery at the referred clinic and assessed for surgical complications and location of the testes.

Results:

During the study period a total of 232 children underwent orchidopexy for UDT in GNCPS. Regarding age of presentation; 1.3% (n= 3) of cases were under 6 month old, 17.2% (n=40) their age was ranging between 6 month and 2 years and the rest 81.5% (n=189) were older than 2 years. All the children included on the study were term baby at delivery. The discovery time for the undescended testis by the parents and the first time for seeking medical advice are summarized in Table 1.

EDITORIAL

There was family history of similar condition in 5.6% (n=13) of the patients presented to the center. In seven of them there was similar history in first degree relatives and in the other six patients in second degree relatives.

In These 232 children; 16.8% (n=39) had bilateral empty scrotum and 83.2% (n=193) were had unilateral empty scrotum. Of those 193 unilateral cases 111 (57.51%) were left sided and the rest 82 (42.49%) were right sided.

On examining the children 63% (n=146) of the testes were palpable as follows:, 66% were palpable just around the superficial inguinal ring, 17.7% were in the mid inguinal area and 16.3% of them were on the upper scrotum (Figure 1).

Orchidopexy was done on the right for 105 and on the left side for 127 children.

There are different methods used to fix testes on the scrotum on performing open orchidopexy with fixation on the Dartos pouch being the most commonly used 79.8%.

The operative time was ranging between 20 minutes and 120 minutes but most (65.1%) of the operations last between 45 and 60 minutes. Most of the patients were discharged from hospital in less than five days. About 89.5% of the patient underwent open orchidopexy and 10.2% of the patient underwent laparoscopic orchidopexy. The location of the testes was in the bottom of the scrotum in 71.9% of patients underwent open orchidopexy.

Discussion:

Patients with UDT frequently present to GNCPS. Most of patients were older than 2 years when comparing this with Thorup et al results which state they used to do orchidopexy at the age of 6–12 months, anyway before the age of 18 months. ⁽¹¹⁾ In this study the children were of relatively older age at presentation. This could be explained by several factors. Part of it is a result of the absence of well designed system to examine the new born children; as two thirds of the cases were discovered by their families to have UDT at born, but only few of them consulted a doctor immediately. Other causes of this delay on counselling include illitracy, lack of knowledge about the problem, fear of social stigma and financial problems. Gezira state introduced the preliminary school screening program; this program can help in both detecting UDT and convincing families with management.

World records about UDT stated that it can affect one or both testes and approximately 10 percent of cases are bilateral ⁽¹²⁾. Among the unilateral cases, a left-sided predominance exists ⁽¹³⁾. These percentages in patients presented to GNCPS were slightly different as the bilateral cases were higher (16.8%). The unilateral cases matched the records as the left side was more common in the study group.

EDITORIAL

Table (1): Time of detection of UDT by parents and first consultation of a doctor

First detection by parents and consultation of a doctor				
At birth	Within 6 months	6-12 month	Later	Total
8	77	56	91	232

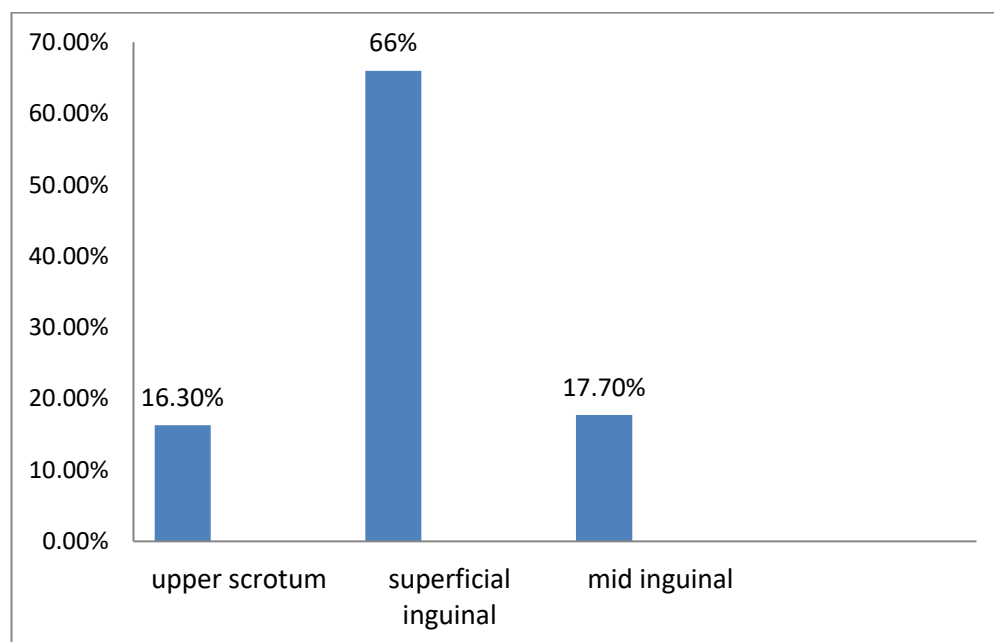


Figure (1): The most common sites for the undescended testis

Positive family history of UDT was discussed in literature. In one study done in 2003 by Elert et al in Department of Urology and Pediatric Urology- Philipps-University Marburg Germany, stated that "In our series the presence of UDT is much more frequently presented than described in the literature. Due to the high familial cluster and the higher percentage of a positive family history for UDT and/or other urogenital anomalies in patients with UDT, a genetic predisposition is probable. Male descendants show a 3.6-fold increased risk in relation to the normal population, if a family member is already affected". They found

EDITORIAL

(22.73%) of their analyzed patients had family members with UDT ⁽¹⁴⁾. Also Schnack et al found the recurrence risk ratios (RRR) among first-degree relatives was significantly higher among brothers (RRR=3.52, 95% CI: 3.26, 3.79) than for off spring of a UDT case (RRR=2.31, 95% CI: 2.09, 2.54) ⁽¹⁵⁾.

In this study only 13 (5.6%) children had positive family history of UDT. There was no significant difference between first and second degree relatives as the incidence in first degree was higher by only one case. This low incidence of the UDT in our patients may reflect the fact that some Sudanese families consider the problem as social stigma and that it affect their child manhood and fertility so they used to hide it and deny its occurrence in their family.

A number of classification systems have been devised, Kaplan (1993) proposed the most popular system, which categorizes cryptorchid testis as either palpable or nonpalpable ⁽¹⁹⁾. Many articles found that approximately 20 percent of boys who present with UDT have at least one non-palpable testis. ^(13, 14, 16, 17)

In this study 36.6% of UDT children had nonpalpable testis and 63.4% had palpable testes by clinical examination. Most testes found were in the superficial inguinal area just around the external ring, followed by the mid inguinal canal then the upper scrotum area. Ferrer et. al. found the most common location for an undescended testicle just outside the external ring (suprascrotal), followed by the inguinal canal, and finally the abdomen. ⁽¹⁸⁾

In GNCPS they used to investigate patients whose testis cannot be palpated by clinical examination. 82% of the patients with nonpalpable testis had ultrasound scan. The most common site by ultrasound scan was mid inguinal canal followed by superficial inguinal area just around the external ring, intra abdominal, then distal inguinal. In some of the patients (n=6) testes cannot be seen by ultrasound. Despite the literature about the use of ultrasound as an investigation tool for locating the testis in patients of UDT, it is not promising. Ultrasound has a sensitivity of 45% and a specificity of 78%. The positive and negative likelihood ratios are 1.48 and 0.79, respectively. A positive ultrasound result increases and a negative ultrasound result decreases the probability that a nonpalpable testis is located within the abdomen from 55% to 64% and 49%, respectively. ⁽¹⁹⁾

In GNCPS we use ultrasound in patients with non palpable testis to clarify the magnitude of the problem to the parents. Further trial to locate the testis is done after the child is fully anesthetized. In the 86 children with nonpalpable testes 28 were found to be palpable and the rest 24.1% of the total number of patient were still nonpalpable.

During the study period the GNCPS installed a laparoscopic unit, but because of limited experience, at time of study, only two cases underwent laparoscopic orchidopexy, the rest were treated with open orchidopexy with either Dartos pouch fixation, traction stitch or fixation in the lingual canal. Dartos pouch fixation is the commonly used method; 79.8% (n=182) of the children underwent open orchidopexy were treated by this method. Comparing the location of the testes after Dartos fixation with other methods 2 weeks post operation the Dartos pouch fixation has the best result as 90 percent of the patient the testes were in the bottom of the scrotum.

The duration of procedure vary between 25 minutes to more than one and half hour, most of operations take around 45 to 60 minutes 64.1% this variation of procedure time had multiple factors. Some of them is patient related like difficulty in induction or recovery from anesthesia, difficulty in localization of the testes and obese patient. The rest is operator dependant; GNCPS is training facility so doctors learn the procedure under supervision of surgeons, this factor explains prolonged duration of some operation. Patient underwent

EDITORIAL

Dartos pouch fixation or fixation of testis in the lingual canal leave the hospital on the next day if there is no justifications like complication of surgery which is most commonly hematoma as happened in two patients.

Conclusion:

The majority of children with UDT presented at an age older than two year which reflect the delay in diagnosis due to lack of adequate neonatal examination. Dartos pouch fixation was associated with the least hospital stay and post operative complication and optimal result.

References:

1. Kolon TF, Patel RP, Huff DS (2004). "Cryptorchidism: diagnosis, treatment, and long-term prognosis. *Urol. Clin. North Am.* 31 (3): 469–80, viii–ix. doi: 10.1016/j.ucl.2004.04.009. PMID 15313056
2. Cendron M, Huff DS, Keating MA, et al. Anatomical, morphological and volumetric analysis: a review of 759 cases of testicular maldescent. *J Urol.* Mar 1993;149(3):570-3
3. Tzvetkova P, Tzvetkov D. Etiopathogenesis of cryptorchidism and male infertility. *Arch Androl.* Sep-Oct 1996;37(2):117-25.
4. Cortes D, Thorup JM, Visfeldt J. Cryptorchidism: aspects of fertility and neoplasms. A study including data of 1,335 consecutive boys who underwent testicular biopsy simultaneously with surgery for cryptorchidism. *Horm Res.* 2001;55(1):21-7.
5. Huff DS, Fenig DM, Canning DA, et al. Abnormal germ cell development in cryptorchidism. *Horm Res.* 2001;55(1):11-7.
6. Hadziselimovic F, Herzog B. The importance of both an early orchidopexy and germ cell maturation for fertility. *Lancet.* Oct 2001;358(9288):1156-7.
7. Rajfer J, Handelsman DJ, Swerdloff RS, et al. Hormonal therapy of cryptorchidism. A randomized, double-blind study comparing human chorionic gonadotropin and gonadotropin-releasing hormone. *N Engl J Med.* Feb 20 1986;314(8):466-70.
8. Docimo SG. The results of surgical therapy for cryptorchidism: a literature review and analysis. *J Urol.* Sep 1995;154(3):1148-52.
9. Backhouse KM. The natural history of testicular descent and maldescent. *Proc R Soc Med.* Apr 1966;59(4):357-60
10. Whitaker RH. Management of the undescended testis. *Br J Hosp Med.* 1970;4:25.
11. J Thorup, S Haugen, C Kollin, S Lindahl, G Läckgren, A Nordenskjöld, S Taskinen. Surgical treatment of undescended testes. *Acta Paediatr.* 2007 May;96(5):631-7. Epub 2007 Mar 23.
12. Pierre Williot, MD. Complications in pediatric urology. In: *Complications In Pediatric Surgery*, Michael G. Caty, M.D, Philip L. Glick, et al (eds), Informa Healthcare USA 2009. p.427 -428
13. Scorer, CG, Farrington, GH. Congenital Deformities of the Testis and Epididymis. *Postgrad Med J.* 1972 September; 48(563): 569
14. Elert A, Jahn K, Heidenreich A, Hofmann R. The familial undescended testis *Klin Padiatr.* 2003 Jan-Feb;215(1):40-5.
15. Schnack TH, Zdravkovic S, Myrup C, Westergaard T, Wohlfahrt J, Melbye M. Familial aggregation of cryptorchidism--a nationwide cohort study. *Am J Epidemiol.* 2008 Jun 15;167(12):1453-7
16. Kirsch, AJ, Escala, J, Duckett, JW, et al. Surgical management of the nonpalpable testis: the Children's Hospital of Philadelphia experience. *J Urol* 1998; 159:1340.
17. Redman, JF. Impalpable testes: observations based on 208 consecutive operations for undescended testes. *J Urol* 1980; 124:379.
18. Ferrer, FA, McKenna, PH. Current approaches to the undescended testicle. *Contemp Pediatr* 2000; 17:106.
19. Smolko, MJ, Kaplan, GW, Brock, WA. Location and fate of the nonpalpable testis in children. *J Urol* 1983; 129:1204

EDITORIAL