

EDITORIAL

CAUSES OF HEPATOMEGALY IN 60 CASES SUDANESE PATIENTS, GEZIRA CENTRAL SUDAN

**Moawia Elbalal Mohammed MD¹, Osman Khalfalla Saeed FRCP², Ahmed A. Mohamadani FRCP
Path³**

- 1- MD medicine assistant professor , Department of Medicine , University of Gezira
- 2- Profeseor of medicine, Department of Medicine , Faculty of Medicine, University of Gezira
- 3- Professor of Pathology ,Department of Pathology ,Faculty of Medicine University of Gezira.

Correspondent : Dr Moawia Elbalal Mohammed ,Gezira centre for laproscopic Surgery and Endoscopy , Faculty of medicine . university of gezira. Wad Medani Sudan
E mail : moawiaelbalal@yahoo.com

ABSTRACT

Chronic liver disease like: Hepatitis, schistosomiasis and hepatocellular carcinoma (HCC) are common in Sudan. The objective of this descriptive prospective clinicopathological, study is to determine the common symptoms and causes of hepatomegaly, excluding periportal fibrosis due to schistosomiasis as it is a very common cause of hepatomegaly in this area of Sudan. Sixty cases presenting with hepatomegaly to Wadmedani Teaching Hospital were included in this study during the period form March 1996 to September 1997. A protocol including a detailed history, physical examination, blood work up, ultrasonography and liver biopsies, was followed. Thirty five were males and 25 were females. Twenty cases (33.3%) had primary hepatocellular carcinoma (HCC) with a males to female ratio of 7:3. Chronic Active Hepatitis (CAH) was found in 6 cases (10%), while active cirrhosis, metastasis and tinny insufficient specimens accounted for 4 cases (6.6%) each. Chronic Persistent Hepatitis (CPH) and a normal histology were seen in 3 cases for each (5%). This study concludes that HCC was the most frequent cause of hepatomegaly in studied group.

EDITORIAL

INTRODUCTION

The relative frequency of the causes of hepatomegaly varies with the geographic distribution. The commonest causes of enlargement of the liver in adults in Britain have been recorded as cardiac failure, metastatic carcinoma and cirrhosis (2). Chronic liver disease like: hepatitis, schistosomiasis and hepatocellular carcinoma (HCC) are common in Sudan (3). Generally in Sudan 38% of children were infected with Hepatitis A virus (HAV), 10% with Hepatitis B virus HBV (4). Hepatocellular carcinoma (HCC) was reported to be an ever increasing disease in Sudan with specific reference to the last few decades (5). Fath ElRahman studied the association of hepatocellular carcinoma with hepatitis B and hepatitis C virus. 115 subjects were included in the study, 47 patients with hepatocellular carcinoma, 68 were controls. Serology for HBsAg, anti HBcAg and alpha fetoprotein were done in all the study group. HBV was found to be highly prevalent in cases of HCC (83%) with a relative risk of 7 fold increase and HCV on the high side (17%) with 2 fold increase in the relative risk (6). Many studies have been done in neighbouring countries. Jordan M Shennak et al mentioned that cardiac failure was the most frequent cause of hepatomegaly (7).

Pattern of hepatomegaly have not been investigated and documented previously in Wad Medani teaching hospital. The objectives of this study are to determine the common symptoms of patients presenting with hepatomegaly, as well as it causes and to describe the main histopathological features.

METHODOLOGY

The study is a descriptive prospective clinicopathological one. It was conducted in Wad Medani teaching hospital, the main referral hospital in Gezira State, Central Sudan in the period between March 1996 to September 1997. All patients attending Wadmedani Teaching Hospital during the study period, and presenting with hepatomegaly (60 patients) were included in the study. Patients presenting with hepatomegaly secondary to heart failure, showing any degree of periportal fibrosis and myeloproliferative disorders were excluded because they are a contraindication for a TruCut liver biopsy, as they could only be biopsied through a transvenous way (19).

Procedures included a detailed history, physical examination and an ultrasound guided liver biopsies using a TruCut biopsy needle (Travenol laboratory, USA) were done by the first author. All specimens were examined by an experienced pathologist (3rd author). Hepatomegaly was determined on the basis of two criteria. The first criterion is the physical examination with liver enlargement of at least 4cm below the costal margin at the mid –clavicular line and the location of the upper border of the liver dullness by percussion at the 5th intercostal space or

EDITORIAL

above (1). The second one is the ultrasonography which was done by an expert sonologist.

RESULTS

Thirty five cases (58.3%) were males and 25 (41.7%) were females. The mean age of the males was 52.5 years with a range of 16-80 years; the females had a mean age of 46.84 years with a range of 15-70 years.

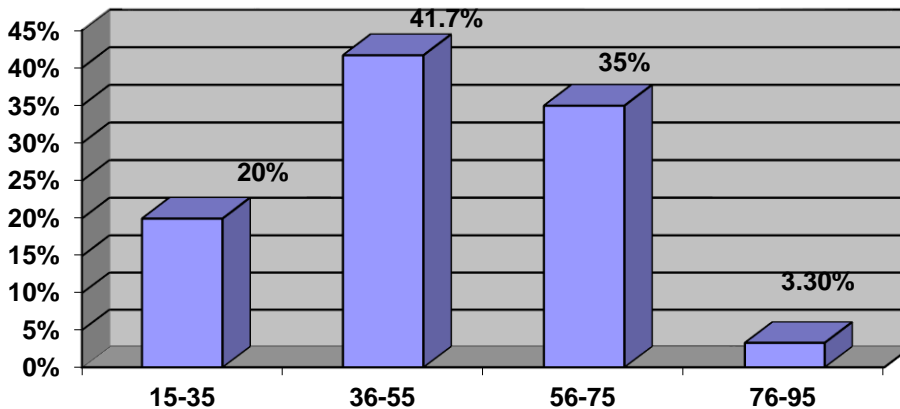


Fig 1: Age range distribution of the study subjects (n = 60)

The main presenting symptoms found in this study are shown in table (1), 27 cases (45%) presented with right hypochondrial swelling dating back to an average of three months . Weight loss was found in 24 cases (40%). Fourteen cases (23.3%) had a right hypochondrial pain, while the rest have abdominal distension 12 (20%), jaundice 7 (11.7%), diarrhea 4 (6.5%) and fever 2 (5%). All patients had hepatomegaly of 4-5 cm below costal margin.

Table (1): the presenting symptoms in the study subjects (n=60)

Presenting symptoms	NO of patients	Percentage %
Right hypochondrial swelling	27	45
Weight loss	24	40
Right hypochondrial pain	14	23.3
Abdominal distension	12	20
Jaundice	7	11.7
Diarrhoea	4	6.7
Fever	2	5

Stigmata of chronic liver disease are shown in figure (2). Four cases (6.7%) were jaundiced , 4 (6.7%) had clubbing of fingers , 4 (6.7%) had a small ascites , 9 (15%) had bruit over the liver and 8 (13 %) cases had splenomegaly . Dilated abdominal wall veins were seen in 3(5%) cases.

EDITORIAL

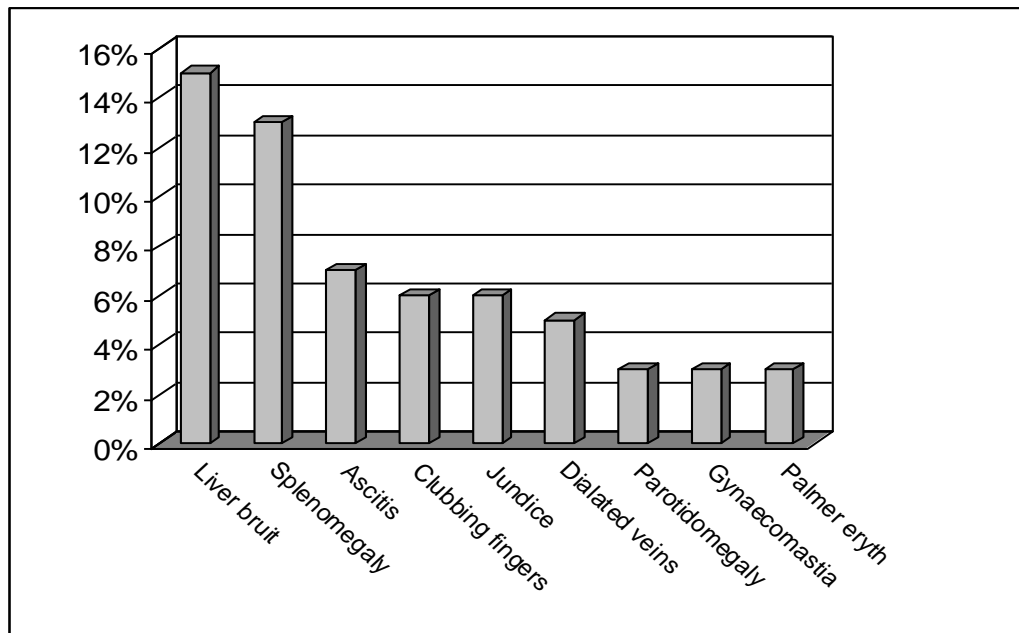


Figure (2) the stigmata of chronic liver disease in study subjects (n=60).

Table 2 shows the liver size in 60 patients with a range between 4cm

to more than 10 cm with a mean liver size of 6.2 cm below the costal margin in the mid-line

Table (2) liver extension below the costal margin in the study subjects (n=60)

Liver Size	4 cm	6 cm	8 cm	10 cm	>10 cm
No. of patients	12	15	13	8	12
Percentage %	20	25	21.6	13.3	20

EDITORIAL

The most frequent histological diagnoses of hepatomegaly found in this study are shown in table (3). Twenty cases (33.3%) had primary hepatocellular carcinoma (HCC) with male: female ratio of 7:3. Chronic Active Hepatitis (CAH) was found in 6 cases (10%), while active cirrhosis, metastasis and tinny insufficient specimens accounted for 4 cases (6.6%) for each. Inactive hepatitis (Chronic Persistent Hepatitis (CPH)) and a normal histology were seen in 3 cases for each (5%).

Table (3) Most frequent histological diagnosis of the study subjects (47/60).

Histological Diagnosis	No. of patients	Percentage %
Primary Hepatocellular Carcinoma	20	33.3
Chronic Active Hepatitis (CAH)	6	10
Active Cirrhosis	4	6.6
Chronic Persistent Hepatitis (CPH)	3	5
Normal Histology	3	5
Tinny Insufficient Specimen	4	6.6
Metastasis (secondaries)	4	6.6
undetermined	3	5

The less frequent histological diagnoses of hepatomegaly are shown in Table (4). Two cases (3.3%) for each of amyloidosis , tropical splenomegaly syndrome, dysplasia and tuberculosis. 1.6% (one case) for each of multiple abscesses , malarious liver (liver that contains malaria pigments), Hepatocyte hyperplasia , congested portal tracts and focal necrosis undetermined histology was seen in 3 cases.

Table (4) less frequent histological diagnosis in the Study subjects (13/60)

Histological diagnosis	NO of patients	Percentage %
Amyloidosis	2	3.3
Tropical Splenomegaly syndrome (TSS)	2	3.3
Dilated sinusoids with dysplasia	2	3.3
Tuberculosis	2	3.3
Multiple abscesses	1	1.6
Malarious liver (Kupffer cell hyperplasia with haemozoin)	1	1.6
Hepatocyte hyperplasia	1	1.6
Congested portal tracts	1	1.6
focal necrosis	1	1.6

Regarding ultrasonography diagnosis it was conforming to histopathology in 41 cases as negative with a false positive in 10 cases and false negative in 12 giving a sensitivity of 75.6% and a low specificity of 36.8% as calculated by cross tabulation.

DISCUSSION

Patterns of hepatomegaly have not been investigated and documented previously in Wad Medani Teaching Hospital. In this clinicopathological study, the aetiological factors of liver enlargement as well as symptoms and signs were analyzed in 60 Sudanese patients seen at Wad Medani

EDITORIAL

Teaching Hospital, with a mean of liver size 6.1 cm as shown in table (2).

Liver palpability alone is not a useful indicator of hepatic size or disease (8,9). The liver edge normally descends 1-3 cm with deep inspiration (10). The location of the upper border of the liver dullness by percussion and body habitus were taken into consideration on physical examination. The second procedure for determining hepatomegaly is by ultrasonography no comparison was done between the two methods.

The results of this clinicopathological study showed that primary hepatocellular carcinoma(HCC) , chronic active hepatitis(CAH) , active cirrhosis and metastatic carcinoma constituted the major groups of liver disease diagnosed on tissue biopsy . This was comparable with other studies from Saudia Arabia (11,12, 13) .

HCC was the first and commonest cause of liver enlargement in this study (33.3%) in contrast to Jordanian group studied by M. M Shennack et al (3.8%) (7). It was the third cause of liver disease (7.2%) in Saudia Arabia group, that was studied by Fashir B. et al (11). while no HCC was encountered by I. Al Mofleh in his series of 100 patients (12). Abdulaziz –Alquorian et al reported HCC (25%) as the third cause of liver disease in his study (13). Data similar to these findings were found in Tropical Africa and South East Asia (14).

The mean age of patients with HCC was 55 years in this study with a male to female ratio of 7:3 and it was similar to the group studied by Fath-EIRhaman (6).

Most of the patients with HCC were farmers, some of them had jaundice 2 (10%) and few of them consumed alcohol 3 (15%). It has been reported that agricultural occupations and pesticides exposure were found be associated with increased risk of HCC (15). Food lacking certain essential vitamins (e.g. pyridoxine) has been reported with an increased risk of HCC (14). Possible dietary causes include consumption of aflatoxin contaminated peanut. Hepatitis B and hepatitis C were not investigated in this study because they were not included as etiological causes in the study objectives.

Chronic Active Hepatitis (CAH) was seen in 10 % of the patients, a figure higher than that reported by Abdulaziz-Alquorain et al from Saudia Arabia (13).

EDITORIAL

The figure is higher than that reported by Almofleh-I from Saudi Arabia (12), but is comparable to that obtained by B.Fashir et al from Saudi Arabia (11). However the figure 10 % is much lower than that reported from King Faisal Specialist Hospital in Riyadh, a referral centre where (26%) of patients had chronic active hepatitis (CAH) (16). Active liver cirrhosis was seen in 6.6% of the cases, a figure very much lower than that reported by B.Fashir, Abdulaziz and Almofleh, I. from Saudi Arabia. The figure is comparable with that of a Jordanian series (9.5%) (7).

Chronic persistent hepatitis (CPH) was encountered in 5% of cases, a figure higher than that reported by Abdulaziz –Alquorain et al (2.3%)(13) and by Kassimi (1.6%) (17). It is comparable with that reported by Al Adnani from Kuwait (6.2%)(18), but is much less than that reported by Almofleh, I. from Saudi Arabia (14%)(12).

Secondary malignant disease was reported in 6.6% of cases. In all the cases the origin (primary site) could not be determined. The figure is somewhat comparable with that reported by Kassimi (8.9%) (17), but is far less than that reported by Abdulaziz (12.9%) (11), and that of the Jordanian series (19.6%) (12).

Tropical splenomegaly syndrome (TSS) was seen in 2 (3.3%) of the cases. All of these patients presented with repeated attacks of malaria as well as gross hepatosplenomegaly. Liver cell dysplasia was found in 2 (3.3 %) cases. These patients could have a definitive pathology e.g HCC as it is possible that a representative specimen was not obtained.

In conclusion, this study showed that hepatocellular carcinoma is a common cause of hepatomegaly in this region and further research should be done to look for possible etiological factors. A TruCut biopsy needle was used and it will be of interest to see if Menghini needle biopsy could give better results. Some researchers used open wedge biopsy which gave excellent results.

ACKNOWLEDGEMENT

My great thanks and gratitude to Prof Ahmed Hamad Nuri for statistical analysis and Dr. Nagla Gasmelseed for finalizing the manuscript

REFERENCES

- 1- Macleod, J: Clinical Examination . 7th edition 1986 . Edinburgh : Churchill Livingstone pp 20-22.
- 2- Bouchier ,I.A.D and Morris ,J.S : Clinical skills ,Second Edition .London , Philadelphia and Toronto : W.B.Saunders CO .
- 3- Department of statistics :Medani Teaching Hospital , Statistic 1995 .
- 4- Hymas K.C,Hussain M.A.M,AL Arabi M.A,Atala N-A,Eltigani A and Mc

EDITORIAL

- Carthy: Acute Sporadic Hepatitis in Sudanese children .Journal Of Medical Virology 1991 ,33,37-76 .
- 5- Daocead E.H et al :Cancer in Africa (1st edition) : Peter Clifford , C, A .Linsel and G.L.Timmas (eds) East Africa Publishing house , Nairobi .
 - 6- Fath Elrahman Khogali : The association of Hepatocellular Carcinoma With Hepatitis B and Hepatitis C Virus among Sudanese patients :Athesis submitted In partial fulfillment for degree of medical doctrine in clinical pathology ,University of Khartoum 1994 .
 - 7- Shennak M.M , Torawenh,MS. Torawneh S.S.,Amr,T.M.AL Skeikh, T. Abu Rajab and S.S Gree : pattern of Hepatomegaly in Jordanians : a prospective study of 800 cases . annuals of Tropical Medicine and Parasitology vol 79, No 4,443-448
 - 8- Cerelek S , Sivacki J et al : How frequency is a palpable liver to be found During systemic Examination of apparently healthy population Acta Hepato spleno (Stuttgart) 1971,18;` 397-402 .
 - 9- Rosenfield A T , Lanfer et al : The significance of a palpable Liver . The American Journal of Roentgenology , Radium Therapy and nuclear medicine 1974 , 122,213 -217 .
 - 10- Petersadorf R.G, Adams R-D,Brauwald E,Issebacher .K.J, Martin.J.B and Wilson J.D:Harrison principle of internal medicine ,10 th edition ,New York:Mc Grow .Hill P208
 - 11- Fashir B et al : pattern of liver disease in a Saudi patient population at Security Force Hospital, Riyadh ,KSA . The Saudi J of Gastroenterology ,Vol2, No1 Jan. 1996,50-52
 - 12- Almofleh I : The pattern of Chronic liver disease in hospital population in Riyadh . East Africa med Journal 1988; 65,514-9
 - 13- Abdulaziz AL Qurian , Mohamed B . Satti , Abdul Rahman AL Hamadan , Yousuf AL Gindan , Ezzeldin Ibrahim, Raeda Khatib, H.AL Freihi : Pattern of chronic liver disease in the eastern province of Saudi Arabia , Tropical and Geographical Medicine 1994 vol . 49 No . 6,358-360 .
 - 14- Cook GC : Hepatocellular Carcinoma In Tropical Gastroenterology ,Oxford- Oxford University Press 1980,P122-135 .
 - 15- Steamhagen A et al :Occupation risk factors and liver cancer . AM.J of Epidemiol.1993,117 (4) 433-53 .
 - 16- Kingston ME , Ashraf MA ,Atiyeh M, Downely R J :Diagnosis of Chronic active hepatitis : a review of 100 cases . King Faisal specialist hospital Med J 1984, 4:9-16 .
 - 17- AL Adnani MS ,Ali S M: pattern of Chronic Liver disease in Kuwait with special reference to Localization Of HBSAg . J clin pathol 1984 , 37 : 549 -54
 - 18- Kassimi M A,Ali M ,Zimmo. S K, Khan M A , and Anees A M : Pattern of

EDITORIAL

liver disease in the western region of Saudi Arabia . Ann Trop med parasit 77;179, 1993.
19- Neil McIntyre et al Oxford text book of clinical hepatology Vol.(1)Oxford University press
1992 pp 321-322