

CASE REPORT

Interventional Ultrasound for Ovarian Cyst Aspiration During Pregnancy; A Case Report and Literature Review

Sami M Abdelkhair ¹, A.Ashmaig ², Badreldeen Ahmed ³, Elhadi Miskeen ⁴

1. Consultant Ob/Gyn and Advanced Ultrasonography, Reproductive Health Care Centre Khartoum, Sudan

2. Professor Ob/Gyn, National Ribat University and Reproductive Health Care Centre Khartoum, Sudan

3. Professor Ob/Gyn and Feto–maternal medicine , Hamad Medical Corporation Feto– maternal Unit Women’s Hospital – Doha – Qatar and Weill Cornell Medical College

4. Teaching Assistant and Registrar Ob/Gyn, Faculty of Medicine, University of Gezira

Correspondence: Dr. Sámi Mahmoud Abdelkhair, Reproductive Health Care Centre, Fetal Medicine Department, Mac Nemir Street, Khartoum, Sudan, P.O.Box 10026, Tel: 00249 183 788630, Fax: 00249 183 587720

Abstract:

Herewith we present perinatal outcome in pregnancies with ovarian cysts after fine needle aspiration in the second trimester and excision during c-section at term. Outcome was satisfactory for both maternal and fetal. 28 years primigravida presented with huge ovarian cyst, size 18 X 16 cm in her second trimester of pregnancy.

The procedure was performed without anaesthesia under ultrasound guidance. Three litres were aspirated within two hours while the patient was on her right lateral position. Cytology of the aspirated fluid revealed a simple ovarian cyst and no evidence of malignancy. The pregnancy continued uneventfully. C-section was done at 37 weeks gestational age. Ovarian cystectomy was performed. The result of histopathology was benign cystadenoma.

We concluded that ovarian cyst aspiration under ultrasound guidance is simple, safe and useful in the management of ultrasonically benign ovarian cysts. We advocate using this procedure in similar situation and same characteristics.

Keywords: ovarian cyst, aspiration, ultrasound guidance.

Introduction:

In a number of pregnant women benign ovarian cysts are found incidentally during routine ultrasound examination or after episode of pelvic pain in early pregnancy ⁽¹⁾. The vast majority are physiologic ⁽¹⁾ or benign tumors that can be

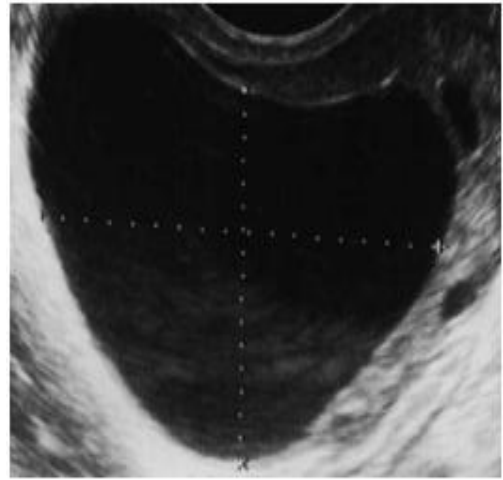
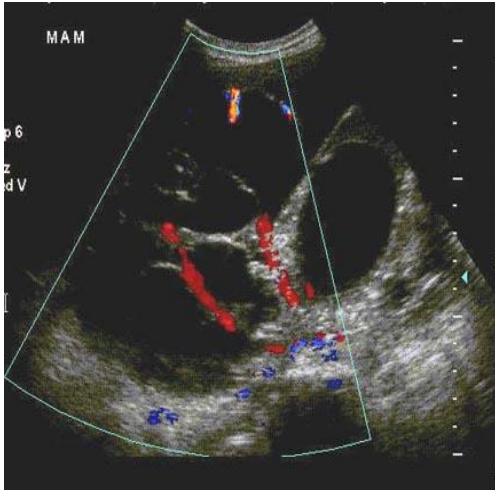
managed expectantly⁽²⁻⁸⁾. In patients managed expectantly, 51 to 70 percent of adnexal masses resolved during pregnancy; risk factors for persistence were size greater than 5 cm and complex morphology on transvaginal ultrasonography.^(3, 9-13) Approximately 10 percent of adnexal masses that persist during pregnancy are malignant^(2, 14, 15). A substantial portion of these are epithelial low malignant potential tumors or germ cell tumors, both tumors with a typically favorable prognosis.

The reported rate of complications with expectant management was less than 2 percent⁽¹⁶⁾. Most persistent adnexal masses are pushed well out of the pelvis as pregnancy progresses by the enlarging uterus. Occasionally, however, an ovarian tumor may be located in the posterior cul-de sac, even at term. A tumor in the posterior cul-de-sac can obstruct delivery or may rupture.

Some ovarian tumors are so large that they appear to be incompatible with an advancing pregnancy. Such a tumor may accommodate in shape and become less problematic, as it is gradually pushed into the upper abdomen. Management of large or impacted benign appearing adnexal tumors during pregnancy must be individualized^(2-7, 17).

However, as pregnancy progresses beyond the first trimester, surgery poses other problems: operative exposure diminishes and the need to manipulate the pregnant uterus increases. Elective surgery for an adnexal mass any time prior to term increases the risk of pregnancy loss and the likelihood of intrauterine growth retardation and preterm delivery^(15,18,19). Adnexal surgery during the late second or early third trimester may pose the greatest risk. The conventional wisdom is to electively operate for an adnexal mass during the early to mid-second trimester. Operating at this point in pregnancy still affords some pelvic exposure without the need for significant uterine manipulation and has been associated with a lower risk of pregnancy complications. The other window for operation is at the time of cesarean section.

In This case we suggest the transabdominal needle aspiration under ultrasound guidance is procedure of choice in huge ovarian cyst in pregnancy and excision later during c-section.

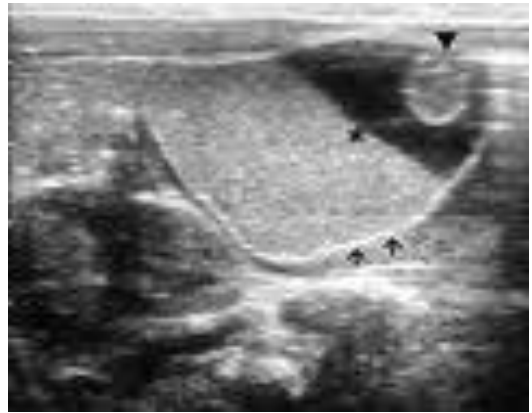
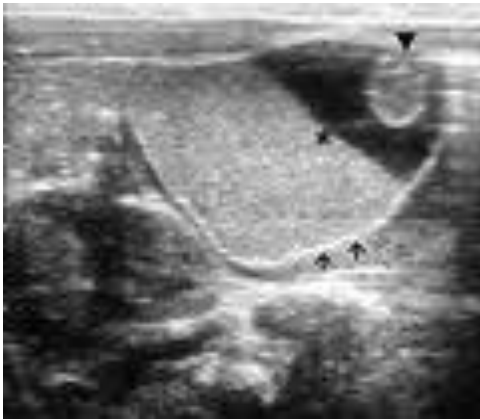


Case Report:

A 28 years old primigravida (PG), married for 18 months presented to the Reproductive Health Care Centre with huge ovarian cyst, size 18 X 16 cm with pregnancy. All her blood and urine investigations were within normal limits. Ultrasonography revealed single live active fetus, 15 weeks. The cyst looked simple ovarian cyst, unilateral, no solid component, no projections from the wall and colour Doppler did not show any increased vascularity.

Blood pressure (BP) was 140/100mm/Hg and she was on Methyldopa. She was planned for laparotomy somewhere else but she came seeking for second opinion. Counselling and comprehensive explanation to patient were done. The patient opts for Ultrasound guided aspiration of the cyst.

The procedure was performed in our fetal unit without anaesthesia under ultrasound guidance using an ovum aspiration pump from in vitro fertilized (IVF) unit. Three litres were aspirated within two hours while the patient was on her right lateral position. Aspirated fluid sent for cytology. Cytology revealed a simple ovarian cyst and no evidence of malignancy. The pregnancy continued uneventfully apart from the mild pregnancy induced hypertension (PIH). We followed the cyst from then till term by serial regular ultrasound. She delivered at 37 weeks gestational age (GA) by caesarean section (C/S) a healthy boy weight: 2.8 Kg.. Ovarian cystectomy was performed. The result of histopathology was benign cystadenoma.



Discussion:

Ovarian cyst aspiration under ultrasound guidance is simple, safe and useful in the management of ultrasonically benign unilocular ovarian cysts. It is of particular use in pregnancy, and in patients unsuitable for laparoscopy or surgery.

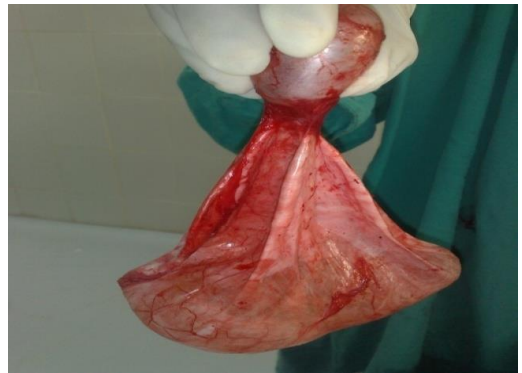
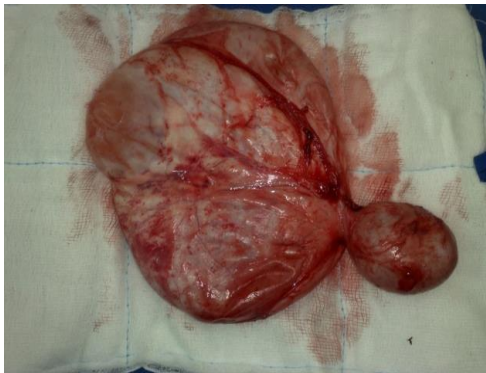
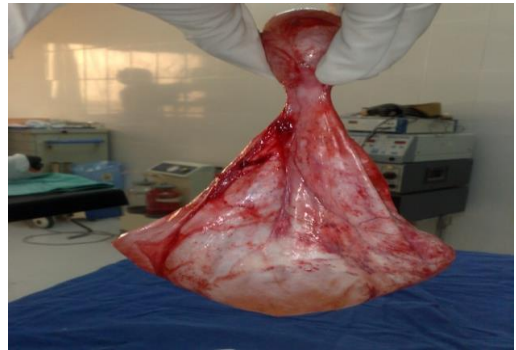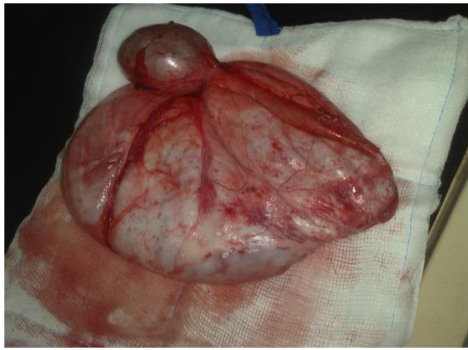Surgery can be reserved for cysts which recur after aspiration, cysts with a haemorrhagic aspirate, cysts in post-menopausal women and those with ultrasonic criteria of malignancy.⁽²⁰⁾

Differential diagnosis includes: uterine leiomyomas, non pregnant horn of bicornuate uterus, appendiceal abscess, diverticular abscess, pelvic kidney, retroperitoneal tumours, ectopic pregnancy and retroverted gravid uterus⁽²¹⁾.

Complications of the cysts associated with pregnancy are torsion of the cyst, rupture, infection, malignancy, impaction of cyst in pelvis causing retention of urine, obstructed labour and malpresentations of the fetus⁽²¹⁾.

Its most common cause in pregnancy is a corpus luteum cyst, which usually regresses spontaneously by the second trimester⁽²²⁾. Ovarian torsion, therefore, occurs most frequently in the first trimester, occasionally in the second, and rarely in the third⁽²³⁾.

Conservative treatment of ovarian torsion via ultrasound-guided transabdominal cyst aspiration and body repositioning represents a reasonable alternative to surgical intervention in the pregnant woman.



Figures: show a group of photos of the cyst after being removed by surgery.

Conclusion:

Ultrasound examination is the most valuable diagnostic study in the evaluation of an ovarian mass. Treatment options during pregnancy are limited. Avoid more invasive procedures like laparoscopy and laparotomy in many cases of ovarian cysts.

Consent

Written informed consent was obtained from the patient for publication of this case report.

References:

1. Jan Oleszczuk, Bożena Leszczyńska-Gorzela, Krzysztof Kamiński, Włodzimierz Baranowski. Evaluation of ovarian cysts by means of transabdominal fine needle aspiration or laparotomy in pregnant women. *Ginekologia polska*. 05/2002; 73(4):367-70.
2. Hoffman, MS, Sayer, RA. Adnexal masses in pregnancy. *OBG Management* 2007; 19:27.
3. Zanetta, G, Mariani, E, Lissoni, A, et al. A prospective study of the role of ultrasound in the management of adnexal masses in pregnancy. *BJOG* 2003; 110:578.
4. Sherard GB, 3rd, Hodson, CA, Williams, HJ, et al. Adnexal masses and pregnancy: a 12-year experience. *Am J Obstet Gynecol* 2003; 189:358.
5. Agarwal, N, Parul, Kriplani, A, et al. Management and outcome of pregnancies complicated with adnexal masses. *Arch Gynecol Obstet* 2003; 267:148.
6. Schmeler KM, Mayo-Smith WW, Pelpert JF, Weitzen S, Manuel MD, Gordlinier ME. Adnexal masses in pregnancy: surgery compared with observation. *Obstet Gynecol* 2005; 105:1098.
7. Caspi, B, Levi, R, Appelman, Z, et al. Conservative management of ovarian cystic teratoma during pregnancy and labor. *Am J Obstet Gynecol* 2000; 182:503.
8. ACOG Practice Bulletin. Management of adnexal masses. *Obstet Gynecol* 2007; 110:201.
9. Bernhard, LM, Klebba, PK, Gray, DL, Mutch, DG. Predictors of persistence of adnexal masses in pregnancy. *Obstet Gynecol* 1999; 93:585.
10. Platek, DN, Henderson, CE, Goldberg, GL. The management of a persistent adnexal mass in pregnancy. *Am J Obstet Gynecol* 1995; 173:1236.
11. Bromley, B, Benacerraf, B. Adnexal masses during pregnancy: accuracy of sonographic diagnosis and outcome. *J Ultrasound Med* 1997; 16:447.
12. Sunoo, CS, Terada, KY, Kamemoto, LE, Hale, RW. Adnexal masses in pregnancy: occurrence by ethnic group. *Obstet Gynecol* 1990; 75:38.
13. Spitzer, M, Kaushal, N, Benjamin, F. Maternal CA-125 levels in pregnancy and the puerperium. *J Reprod Med* 1998; 43:387.
14. Hoffman, MS. Primary ovarian carcinoma during pregnancy. *Clin Consul Obstet Gynecol* 1995; 7:237.
15. Leiserowitz GS, Xing G, Cress R, et. al. Adnexal masses in pregnancy; how often are they malignant? *Gynecol Oncol* 2006; 101:315.
16. Whitecar, MP, Turner, S, Higby, MK. Adnexal masses in pregnancy: a review of 130 cases undergoing surgical management. *Am J Obstet Gynecol* 1999; 181:19.

17. Caspi, B, Ben-Arie, A, Appelman, Z, et al. Aspiration of simple pelvic cysts during pregnancy. *Gynecol Obstet Invest* 2000; 49:102.
18. Mazze RI, Kanen B. Reproductive outcome after anesthesia and operation during pregnancy; a registry study of 5,405 cases. *Am J Obstet Gynecol* 1989; 161:1178.
19. Reedy MB, Kanen B, Kuehl TJ. Laparoscopy during pregnancy: a study of five fetal outcome parameters with use of the Swedish health registry. *Am J Obstet Gynecol* 1997; 177:673.
20. K T Khaw, W J Walker. Ultrasound guided fine needle aspiration of ovarian cysts: diagnosis and treatment in pregnant and non-pregnant women *Clinical radiology*. 03/1990; 41(2):105-8.
21. Lee CH, Raman S, Sivanesaratnam V. Torsion of ovarian tumors: a clinicopathological study. *Int J Gynaecol Obstet*. 1989;**28**:21–25. doi: 10.1016/0020-7292(89)90539-0.
22. Duic Z, Kukura V, Ciglar S. Adnexal masses in pregnancy: a review of eight cases undergoing surgical management. *Eur J Gynaecol Oncol*. 2002;**23**:133–134.
23. Hibbard LT. Adnexal torsion. *Am J Obstet Gynecol*. 1985;**152**:456–461.