

Primary Tuberculosis of the Maxillary Sinus:

A case report.

Wail N. Osman¹, Osman M. El-Mustafa¹, Mohammed Elawad Elsiddig²

1. Consultant ORL H & NS and Assistant professor, **Department of Surgery, Faculty of Medicine, University of Gezira**, P.O. Box 20, Wad-Medani, Sudan

1. Professor and senior consultant of ORL, H & NS, **Department of Surgery, Faculty of Medicine, University of Gezira**. P.O. Box 20. Wad- Medani. Sudan.

2. Registrar of Otorhinlaryngology, Sudan Medical Specialization Board (SMSB), Sudan.

Adress of crospondence:

Dr. W. N. Osman

Faculty of Medicine, University of Gezira, P. O. Box: 20. Wad Medani, Sudan

Tel.: 00249-511-854279. Mobile Tel.: 00249-925109052. Fax: 00249-84345

E-mail: wailnuri2000@yahoo.co.uk.

Abstract:

Tuberculosis is up-to-date a leading cause of human suffering and loss of life. Although tuberculosis is a systemic disease, primary tuberculosis of the paranasal sinuses is rare. It should be kept in mind in any undiagnosed or atypical clinical infection or inflammation in this region. We present here a case of primary paranasal sinuses tuberculosis in an elderly Sudanese woman. Although Sudan is one of the highest three countries in the incidence of tuberculosis, this is the first case to be reported in Sudan.

Key words: Tuberculosis, maxillary sinus, Sudanese

ملخص: الإصابة بالدرن من أهم المسببات للمعاناة البشرية وفقدان الأرواح. الدرّن الذي يصيب الأنف و الجيوب الانفيه هو نادر الحدوث حتى في المرضى المصابين بالدرن في الأعضاء الأخرى من الجسم ولكن يجب وضعه في الاعتبار في حالات الأخمّاج والالتهابات الغير مشخصة أو اللانمطية . نقدم هنا اصابة درن اولية في الجيب الانفي في سيده سودانيه مسنه. والسودان وبالرغم من انه احد البلدان الثلاث الأكثر إصابة بالدرن إلا إن هذا هو تقرير الحالة الأول من نوعه في السودان .

Introduction:

Tuberculosis is a leading cause of human suffering and loss of life. Despite that Sudan being one of the three countries of the highest incidence of tuberculosis, we report the first case of primary paranasal

EDITORIAL

sinuses tuberculosis. Although primary tuberculosis of the paranasal sinuses is rare it should be kept in mind in any undiagnosed or atypical clinical infection in this region.⁽¹⁾ Moreover, it sometimes mimics chronic granulomatous or neoplastic lesions. Hence, high diagnostic suspicion is important. The rarity of this disease can be explained by the protective functions provided by the ciliary action of the nasal mucosa, the bactericidal properties of the nasal secretions and the protective mechanisms of the nasal vibrissae.⁽²⁾ There are mainly three types of pathologies seen in sinonasal tuberculosis. In the first type, infection is confined to mucosa only, leading to polypi filling the antrum and minimal purulent discharge. The second type has bony involvement, fistula formation and abundant discharge teeming tubercle bacilli. The third type is associated with hyperplastic changes and formation of tuberculoma.⁽³⁾

In this report we are presenting a case of primary tuberculosis of the maxillary sinus in an elderly Sudanese woman. To our knowledge this is the first case to be reported in Sudan.

Case report:

A 65 years old lady presented to the Ear, Nose and Throat (ENT) department, Wad-Medani General Hospital, Sudan with a five months history of gradually increasing swelling of her right cheek. The swelling eventually caused her right sided nasal obstruction and blindness of her right eye. There was no history of epistaxis, snoring, excessive tearing or impaired sensation over the cheek. She was not previously diagnosed as a case of pulmonary tuberculosis and had no history of chronic cough, haemoptysis, weight loss, night fever or sweating. There was no family history of tuberculosis and she had no contact with a known patient of tuberculosis. The patient is of low socioeconomic status and lives in a small village nearby Wad Medani city. She sought medical advice, seen first in the Eye Hospital and was then referred for ENT assessment. Examination revealed swelling and deformity of the patient's right cheek overlying her right maxilla and extending to the infra-orbital region and covered with normal skin. The swelling was about 5 cm. X 6 cm. firm in consistency, not hot or tender, with an irregular surface and edges, attached to underlying tissues, but free from the overlying skin, and was not pulsatile or compressible. Nasal examination revealed right nasal obstruction caused by bulging of the lateral nasal wall compromising the nasal airway. There was purulent discharge from left middle meatus. Nasopharyngeal examination was normal. Examination of the eyes demonstrated normal movements in both eyes with blindness of the right eye and normal visual acuity in the left eye. No abnormalities were

EDITORIAL

detected in the ears, oral cavity, pharynx, larynx or neck. Clinical examination of the chest was unremarkable.

Haemogram report revealed a total white cell count of 7000, with a differential of neutrophils-32%, lymphocytes-62%, monocytes-3%, eosinophils-3% and Erythrocyte Sedimentation Rate (ESR) was 54 mm after one hour by Westergreen method. Coronal and axial CT-Scanning of the nose and sinuses with both soft tissues and bone windows revealed soft tissues swelling over the right maxilla with osteomyelitic changes in the anterior wall of the maxilla and extension into the subcutaneous tissues of the cheek and the lateral wall of the right ethmoidal and sphenoid sinuses extending into the optic canal and the orbit (Figure 1 & 2). Serological IgM test for Tuberculosis was positive.

Figure (1): CT Axial View showing soft tissue mass occupying the right maxillary antrum and eroding the anterior wall and extending into the subcutaneous tissues of the cheek.

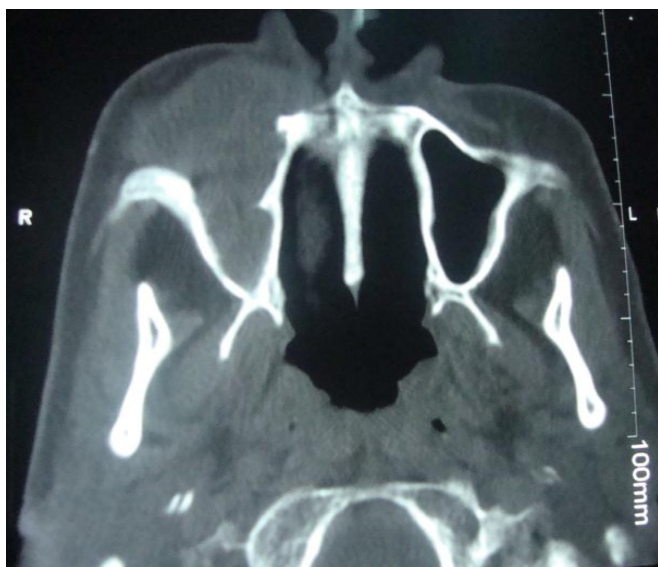
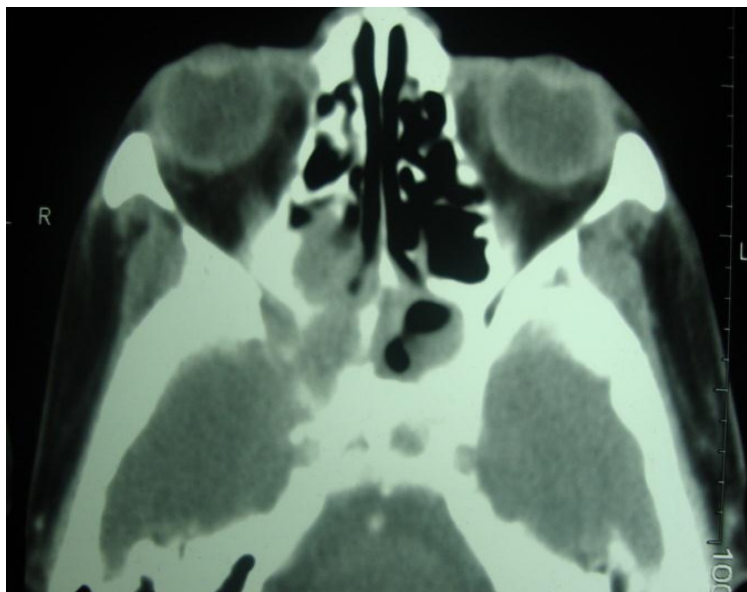


Figure (2): CT Axial View showing soft tissue mass involving lateral wall of the right ethmoidal and sphenoid sinuses and extending posteriorly into the optic canal and orbit.

EDITORIAL



Excisional biopsy was performed through a right sub-labial approach under general anesthesia. A brownish soft tissue mass with granulations was removed and the anterior wall of the maxillary antrum was found to be through the diseased and destroyed. Post operative recovery was uneventful. The specimen was sent for histopathology which revealed necrotizing granuloma with caseation, epithelioid cells, Langerhan's giant cell and lymphocytes. Ziehl Nilseen staining for acid-fast bacillus (AFB) was negative. Staining and culture for fungi were negative. Patient was started on Anti tuberculous treatment and was seen one month after surgery. Nasal obstruction disappeared, nasal discharge stopped and the cheek mass remarkably regressed, but there was no visual recovery.

Discussion:

Tuberculosis is an infectious disease caused by an intracellular acid-fast bacillus demonstrated by the Zeal-Nielsen stain. Tuberculosis of the nose and paranasal sinuses is rare even in patients with tuberculosis of other organs. It was first reported in 1761 by Morgagni. ⁽⁴⁾ Mayerson stated that any sinus may be involved, the most common being the maxillary and ethmoid sinuses. ⁽⁵⁾ This patient had mainly involvement of the right maxillary sinus and the right orbit. Sinonasal tuberculosis commonly presents as an infectious process limited to the mucosa and submucosa. ⁽⁷⁾ The other more aggressive form is characterized by destruction of the bone with extension into the cranial cavity, orbit and the soft tissues of the face. As a result, the patient may present with a brain abscess, epistaxis, visual impairment or a facial abscess. ^(1, 3, 6,7) This patient had bony destruction and extension into the ethmoid and sphenoid sinuses with involvement of the soft tissues of the cheek and destruction of the optic nerve.

EDITORIAL

This condition may be mixed with malignancy and although it is rare it should be considered in the differential diagnosis as it can be cured with antitubercular treatment.

References:

1. Sudanese ministry of health: <http://www.emro.who.int/dsaf/dsa1077.pdf>
2. Kadambari B, Chaudhary N, Motwani G and Rai AK (2002). An Unusual case of primary nasal tuberculosis with epistaxis and epilepsy. *Ear Nose Throat J*; **81**(12): 842-844.
3. Jain MR, Chundawat HS, Batra V (1979). Tuberculosis of the maxillary antrum and of the orbit. *Indian J Ophthalmol.*; 27:18-20.
4. Waldman SR, Levine HL, Sebek BA, *et al* (1981). Nasal tuberculosis: A forgotten entity. *The Laryngoscope*; 91: 11
5. Meyerson, MC (1956). Tuberculosis of the Ear, Nose and Throat. In Coates, Schenck and Miller. *Otolaryngology*, S. W. F. Prior Co., Hagerstown, Maryland,; 5.
6. Shukla GK, Dayal D and Chabra DK (1972). Tuberculosis of maxillary sinus. *J Laryngol Otol*; **86**: 747-754.
7. Jha D, Deka RC and Sharma MC (2002). Tuberculosis of the Maxillary sinus manifesting as a facial abscess. *Ear Nose Throat J*; **81**(2): 102-104.