

**RETROPUBIC PROSTATECTOMY IN 96 PATIENTS IN  
SOBA UNIVERSITY HOSPITAL**

Sami Mahjoub Taha<sup>1</sup>, Abd ElRaouf Sharfee<sup>2</sup>, Adil Ibrahim<sup>2</sup>, Gamal Mustafa<sup>1</sup>

1.General surgeon, university of Gezira ,Faculty of Medicine

2.Urologist,U of K, Faculty of Medicine

**Correspondent author :**

Sami Mahjoub Taha –U of G –Faculty of Medicine –Department of Surgery –e mail samimahj@gmail.com

**ABSTRACT :**

**Background:** Retropubic prostatectomy(RPP), is a good treatment option for men with symptomatic bladder outlet obstruction caused by large size prostate.

**Objective:** To determine the intraoperative, early and late postoperative complications of retropubic prostatectomy. **Methods :**This is a retrospective, small-scale hospital based study conducted in Soba University Hospital, Sudan. We include 96 patients, from Jan 2003 to Jan 2008 who underwent RPP.

**Results:** The mortality rate was zero. Retrograde ejaculation in 50.1% , clot retention due to catheter block in 36.5% and transient urinary incontinence in 24%, all were improved within the first three months postoperatively and intraoperative bleeding was reported in 9 patients (10%). Erectile dysfunction in 7.5% , wound infection in 6.3% , urethral stricture in 5.2% ,urine leakage in 4.2% and injury to adjacent structures(peritoneum–bowel) was not reported.

**Conclusion:** The complications of retropubic prostatectomy in Soba Hospital was found to be comparable to the literature.

**Key words:** Retropubic prostatectomy,Soba teaching hospital, Sudan .

**Introduction :**

Benign prostatic hyperplasia (BPH) is one of the most common diseases in middle-aged and senescent males, and the incidence and importance of BPH have increased as the aged population has increased. As a result, treatments have been diversified and continuously advanced. Among them, transurethral resection of the prostate (TURP) has been recognized as the standard of surgical treatments and has been effective for patients with BPH. In rare cases, TURP is performed on patients whose prostates are voluminous, but in most cases, it is applied to small and moderate-sized BPH. In the case of an excessively voluminous prostate, open simple prostatectomy is performed because complications, such as transurethral resection syndrome or hemorrhage, can occur with TURP and postoperative symptoms may not easily improve<sup>[1]</sup>. Despite the increasing popularity of holmium laser enucleation of the prostate (HoLEP) and evidence that the technique may be superior to conventional treatment modalities. Open simple prostatectomy remains

**EDITORIAL**

the procedure of choice for prostate adenomas too large for safe endoscopic resection [2].

Simple retropubic prostatectomy dates to 1945, when Millin first reported his experience with 20 patients. Consider open (simple) prostatectomy, using either the retropubic or suprapubic approach, when the prostate is larger than 75 g or larger than the surgeon can resect reliably with TURP in 60-90 minutes. In patients with concomitant bladder pathology that complicates their outlet obstruction (eg, a large or hard bladder calculus, symptomatic bladder diverticulum), open prostatectomy remains the procedure of choice. Additionally, patients with musculoskeletal disease that precludes proper patient positioning in the dorsal lithotomy position for TURP may benefit from an open prostatectomy<sup>[3]</sup>.

Advantages of the retropubic technique over the suprapubic approach include the following: anatomic prostatic exposure, direct visualization of the adenoma during enucleation to ensure complete removal, precise division of the prostatic urethra optimizing preservation of urinary continence, direct visualization of the prostatic fossa after enucleation for hemorrhage control and minimal to no surgical trauma to the bladder <sup>[4]</sup>.

Disadvantages of retropubic prostatectomy relate largely to the limited access to the bladder, which is an important consideration if a bladder diverticulum requiring excision coexists or when a large bladder calculus must be directly removed. Additionally, if cystoscopy findings indicate that the obstructing adenoma primarily involves the median lobe, the suprapubic approach may be preferred because this technique optimizes anatomic exposure<sup>[4,5]</sup>.

The overall rate of morbidity and mortality associated with open prostatectomy is extremely low. Historically, excessive hemorrhage had been a major concern. Urinary extravasation can also be of concern in the immediate postoperative period; this most likely results from an incomplete closure of the prostatic capsulotomy in retropubic prostatectomy. It usually resolves spontaneously with continued catheter drainage. The drain should be left in place until urinary extravasation ceases<sup>[6,7]</sup>.

Following an open prostatectomy, urgency and urge incontinence may be present for several weeks to several months, depending on the preoperative bladder status. If the condition is severe, the patient may be given an anticholinergic agent such as oxybutynin (Ditropan). Stress incontinence and total incontinence are rare. With a precise enucleation of the prostatic adenoma, risk of injury to the external sphincter mechanism is minimal. If stress incontinence does result after the procedure, the patient may benefit from transurethral collagen injections for a mild condition or an artificial urinary external sphincter when the situation is more severe<sup>[8]</sup>.

Late urologic complications are not common. Acute cystitis rarely occurs as long as the patient voids to completion. Acute epididymitis can occur occasionally if infected urine refluxes into the ejaculatory ducts <sup>[9]</sup>.

Erectile dysfunction occurs in approximately 3% to 5% of patients undergoing an open prostatectomy; it is more common in older men than in younger men. Retrograde ejaculation occurs in approximately 80% to 90% of patients following surgery. The risk of this adverse effect is reduced if the bladder neck is preserved at the time of surgery. Also, approximately 2% to 5% of patients develop a bladder neck contracture 6 to 12 weeks after an open prostatectomy .. However, if a bladder neck contracture does develop, the initial management should be dilatation with urethral sounds or a direct vision incision of the bladder neck using

## **EDITORIAL**

a Collings knife to create a No. 22 Fr opening in diameter<sup>[9,10]</sup>.

The most common nonurologic adverse effects include deep vein thrombosis, pulmonary embolus, myocardial infarction, and a cerebral vascular event. The incidence of any one of these complications is less than 1%, and the overall mortality rate associated with this operation should approach zero<sup>[10]</sup>.

In Soba hospital retropubic prostatectomy (RPP) is being performed as a routine. In this study we describe the surgical technique and assess the feasibility of open retropubic simple prostatectomy in Soba University hospital .

### **Material and methods :**

This study was conducted on 96 consecutive patients with BPH who underwent open retropubic prostatectomy between Jan 2003 – Jan 2008 in Soba University Hospital,Sudan. The study is a retrospective, small-scale hospital based study. Using a non-probability-based; purposeful-convenient sampling.

The subjects were limited to the patients who satisfied the following inclusion criteria: All men who presented within the defined study period, with features of symptomatic benign prostatic hyperplasia, who underwent retropubic prostatectomy and the result of histopathology was benign prostatic hyperplasia, and had several successive follow up visits (6weeks -6months) .

The diagnosis was established by history and examination including IPSS (International prostate symptoms score ) and digital rectal examination(DRE) .Investigations including urine analysis, renal functions test,PSA (Prostate specific antigen) and cystoscopy was done If indicated .

Data concerning the incidence of intra-and postoperative complications was collected using a data collecting sheet (annexes), then entered using the software SPSS version 11,for analysis. Both dependent and independent variables were displayed as frequency tables; then Chi-square test was used to test the significance of relationship between categorical variables, where only values less than 0.05 were considered as significant.

### **Surgical technique:**

Cystoscopy was performed in men with hematuria, suspected urethral stricture, bladder calculus, or diverticulum. The patient was kept without oral intake after midnight .

The patients were positioned on the operating table in a supine position .A lower transverse Suprapubic incision is made. It is deepened through the subcutaneous tissue. The anterior rectus sheath was opened in transverse manner, allowing the rectus abdominis muscles to be separated in the midline. The transversalis fascia is incised sharply to expose the space of Retzius. And the peritoneum is now mobilized cephalad, starting at the pubic symphysis and being swept anterolaterally. A self-retaining Balfour retractor is placed in the incision and widened.

The prostate and the anterior surface of the bladder is exposed. Dithermomy is used to make a transverse capsulotomy in the prostate 1.5 to 2.0 cm distal to the bladder neck The incision is deepened to the level of the adenoma and extended sufficiently laterally in each direction to permit complete enucleation. Once a

## **EDITORIAL**

well-defined plane is sufficiently developed, the index finger can be inserted between the prostatic adenoma and the capsule to further develop the plane laterally and posteriorly. A pair of Metzenbaum scissors is then used to incise the anterior commissure from the bladder neck to the apex, separating the lateral lobes of the prostate anteriorly. This maneuver is then repeated for the right lateral lobe. If a median lobe is present, the overlying mucosa is incised at the level of the bladder neck and this lobe is removed. If hemorrhage is persistent, a 2-0 vicryl suture can be used to place a figure-of-eight stitch in the bladder neck at the 5- and 7-o'clock positions. Complete control of the dorsal vein complex before proceeding with enucleation of the prostatic adenoma, and packing of the prostatic fossa after enucleation of the adenoma it is important to achieve good hemostasis. After inspecting the bladder for a complete adenoma removal and hemostasis, a No. 22 Fr, three-way Foley catheter with a 20-ml balloon is inserted through the anterior urethra and prostatic fossa into the bladder. With the urethral catheter in place, the prostatic capsule is closed. A 1 vicryl suture on a  $\frac{5}{8}$  circle-tapered needle is used to create two running stitches. These stitches begin laterally and meet in the midline; they are first tied separately and then together to create a watertight closure. The bladder is then irrigated with saline solution to ensure continued hemostasis and to test the capsular closure for leakage. A small, closed-siphon drain is placed via a separate stab incision lateral to the prostate and bladder on one side to prevent hematoma and urinoma formation. Muscle is approximated by vicryl 0/2 and anterior rectus sheath is sutured by vicryl 1.

Postoperatively continuous bladder irrigation is initiated to prevent clot formation. The patient breaks his fast 2-3 hours postoperatively. The pelvic drain is removed if the drainage is less than 50 ml/24 hr. The patient should be able to resume full activity 4 to 6 weeks postoperatively with outpatient visits at 6 weeks and 3 months for postoperative complications.

### **Results:**

Patients' ages ranged between 50 – 90 yrs; with a mean age being 69 yr. The majority of the patients were between 60 -80 yrs. In this study 46 patients out of 96 (47.9%) were from Khartoum State. The study found that 51 patients (53.1%) presented with severe lower urinary symptoms, while the remaining 45 patients (46.9%) presented with acute urinary retention. Figure 1. Among the studied patients, 7 patients (7.3%) were known cases of diabetes mellitus, 10 patients (10.4%) were known hypertensive, and further 5 patients (5.2%) were known to have other different chronic illnesses; such as asthma, gout and rheumatoid arthritis. Thirty three (33.3%) of the patients received medical treatment for prostatic symptoms preoperatively, and 45 patients have been catheterized preoperatively for different periods of time. Urine analysis showed evidence of UTI in 86 patients (87.5%). Prostate specific antigen (PSA) levels varied between 0.3 – 13.8 ng/dl, one patient had PSA level of 13.8ng/dl (Biopsied and the result was BPH), while other patients PSA was below 4 ng / ml. The prostate weight— as estimated using postoperative weight of the adenoma, varied between 35 and 224 g; with a mean weight of 81.5 g, where 25% of the patients had prostate weights more than 106 g.

The Cystoscopy showed bladder trabeculations in all patients. A 39 patients (40.6%) had coexisting bladder stones, and 34 patients (35.4%) had bladder diverticulations. Figure 2. .

Intraoperative bleeding was reported in 9 patients (managed by packing), while injury to internal structures (bowel-peritoneum) was not reported.

Early postoperative complications were clot retention (due to catheter block) in 35 patients (36.5%), wound

**EDITORIAL**

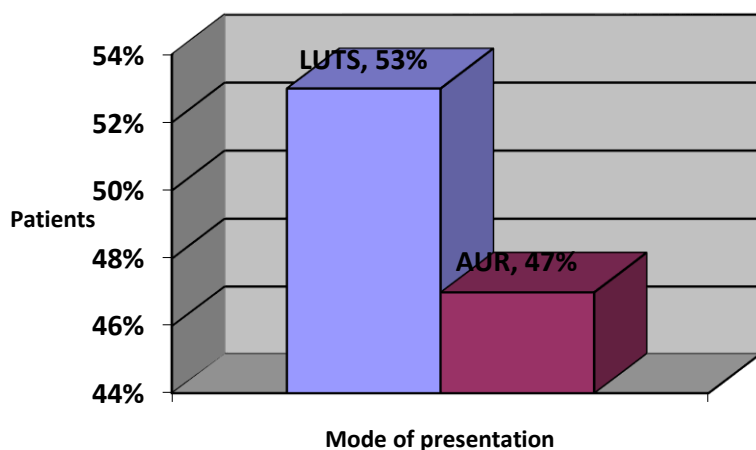
infection in 6 patients (6.3%), early postoperative bleeding in 4 patients (4.2%) and Suprapubic leakage of urine was reported in 4 patients (4.2%), .Figure3

Late postoperative complications were retrograde ejaculation in 47 patients(50.1%) ,transient urinary incontinence in 23 patients (24%), all were improved within the first three months postoperatively, permanent urinary incontinence was not reported, erectile dysfunction in 8 patients (7.5%)and urethral stricture was reported in 5 patients (5.2%) 4 cases were bulbar stricture and one was prostatic urethral stricture..Figure 4

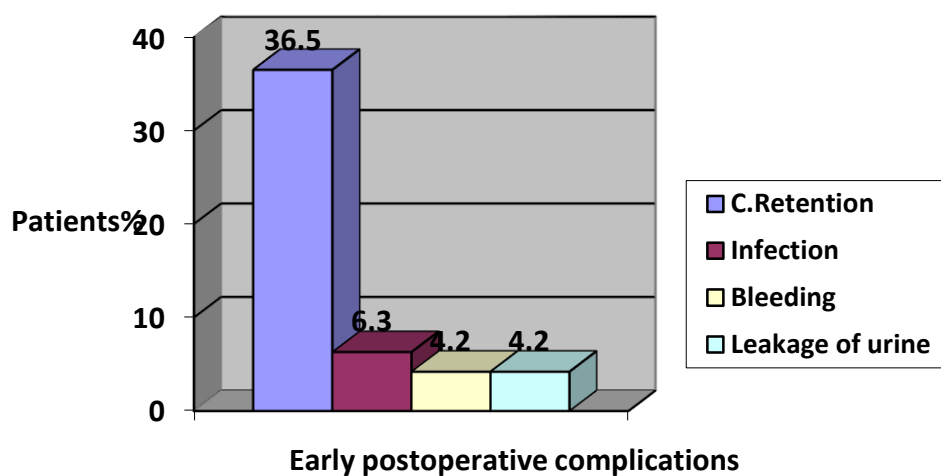
The overall rate of mortality associated with open retropubic prostatectomy was zero.

**Figure 1 : The mode of presentations in 96 patients underwent**

**RPP Soba Hospital, Sudan 2003-2008:**

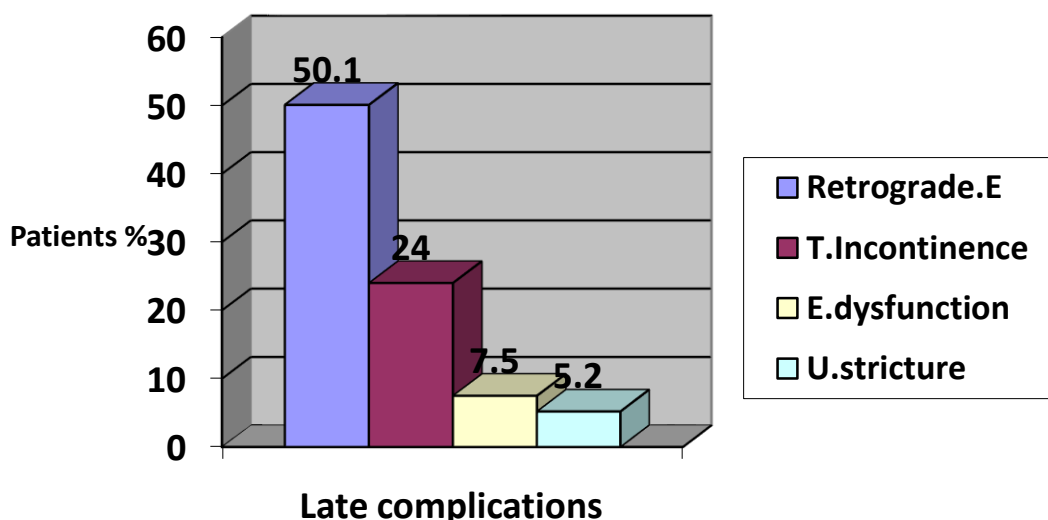


**Figure 2: Early postoperative complications in 96 patients underwent RPP Soba Hospital, Sudan 2003-2008**



**figure 3 : Late postoperative complications in 96 patients**

**underwent RPP Soba Hospital, Sudan 2003-2008**



**Discussion :**

In this study, 46.9% patients presented with AUR which is less than in the Korean<sup>11</sup> and Pakistan<sup>12</sup> studies, where it was 58.3%, and 57% respectively, however, it was higher than what was reported in a study conducted in Iran<sup>13</sup>, as the AUR was only 11.7%. The other mode of presentation was LUTS, which was found in 53.1% of our patient ; taking an intermediate position between the corresponding results at comparative studies; as in Italy<sup>14</sup>LUTS was 85.5% and 38.5% in Pakistan<sup>12</sup>.

Urinary tract infection(UTI)was present in 87.5% of the patient. In study from Nairobi<sup>15</sup> UTI was found in 15% of the patients. The rate of UTI in our study is higher than other studies and that could be due to prolonged preoperative catheterization. The mean duration of preoperative catheterization was 4 weeks in75% of our patients compared with that reported from Nairobi<sup>15</sup> which was 3weeks in 10% of their patients .

In this study, PSA level ranged between I -13.8ng/dl ,in one patients it was 13.8ng/ml inspite of the prostatic histopathology being benign , possibly due to the huge size of the prostate (224g) .

In this study, the weight of the prostate (adenoma) ranged between 35and224 g.; which was nearly similar to those reported from Indian study<sup>16</sup> (68-205 g), while in Korean study<sup>11</sup> the mean was 48 g and in Italy<sup>14</sup>60.2 g. The high incidence of large size prostate in this study favors the increase in frequency of retro pubic prostatectomy .

## **EDITORIAL**

The Intraoperative bleeding reported in this study was found to be in the rate of about 10% (Managed by packing), while in study done in Korea<sup>11</sup> was 0.02%. The high incidence of Intraoperative bleeding in comparison to the Korean study, can be related to the large size of the prostates.

There was no injury to adjacent structures (bowel –peritoneum) in this study, which was in agreement with the same results in Italy<sup>14</sup> and Korea<sup>11</sup>.

Suprapubic urine leak in early postoperative period was 4.2% (Managed by keeping the patient catheterized until leakage stopped), in comparison with Korean<sup>11</sup> and Italian<sup>14</sup> studies, which were 0.04% and 4% respectively; thus, the incidence rate is acceptable.

Clot retention occurred in 36.5% of our study subjects (Managed by flushing the catheter with saline or changing the catheter), which is three times higher than that found in Nairobi<sup>10</sup>, where it was 10%. This high incidence of clot retention (due to catheter block) maybe due to the high incidence of Intraoperative bleeding, as discussed previously.

Wound infection occurred in 6.3% (Managed by reopening of the wound, dressing and later secondary suture), which is more than that reported from Iran<sup>13</sup> (1.2%) and nearly the same as that reported from Italy<sup>14</sup> (6%). The rate of transient urine incontinence was 24%, this similar to that reported in Mumbai<sup>16</sup> (25%), but higher than that reported from Italy<sup>14</sup> (16%). Postoperative urethral stricture was 5.2% this is twice higher than that reported in Mumbai<sup>16</sup> (2%) and Pakistan<sup>12</sup> (2%) and less by four times than that reported in Italy<sup>14</sup> 20%.

In our study, erectile dysfunction showed in 7.5% (managed by drugs), compared with study done in Italy<sup>14</sup> which was 25%. In this study, 50.1% of the patients had retrograde ejaculation (Managed by drugs) which is less than that reported in Italy<sup>14</sup>, where it was 80%.

## **Conclusion :**

The complications of retropubic prostatectomy in Soba Hospital was found to be comparable to the literature. The rate of postoperative wound infection is significant in this study as a result of DM and long preoperative catheterization. Clot retention due to catheter block was the commonest early postoperative complication. Erectile dysfunction showed significant rate.

## **References:**

1. Baek M, Paick SH, Lee BK, Kang MB, Lho YS, Jung SI, et al. The efficacy of bipolar transurethral resection of the prostate in patients with large prostates (>80 g) and analysis of the postoperative results based on the resection ratio. *Korean J Urol.* 2008;49:1087–1093.
2. Baumert H, Ballaro A, Dugardin F, Kaisary AV. Laparoscopic versus open simple prostatectomy: a comparative study. *J Urol.* 2006;175:1691–1694. [PubMed]
3. Sotelo R, Spaliviero M, Garcia-Segui A, Hasan W, Novoa J, Desai MM, et al. Laparoscopic retropubic simple prostatectomy. *J Urol.* 2005;173:757–760. [PubMed]
4. Han M, Partin AW. Retropubic and suprapubic open prostatectomy. In: Wein AJ, Kavoussi LR, Novick AC, Partin AW, Peters CA, editors. *Campbell-Walsh urology.* 9th ed. Philadelphia: Saunders; 2007. pp. 2845–2853.
5. van Velthoven R, Peltier A, Laguna MP, Piechaud T. Laparoscopic extraperitoneal adenomectomy (Millin): pilot study on feasibility. *Eur Urol.* 2004;45:103–109. [PubMed]

**EDITORIAL**

6. Gacci et al., 2003. Gacci M, Bartoletti R, Figlioli S, et al: Urinary symptoms, quality of life and sexual function in patients with benign prostatic hypertrophy before and after prostatectomy: A prospective study. *BJU Int* 2003; 91:196-200.
7. McConnell et al., 1994. McConnell JD, Barry MJ, Bruskewitz RC, et al: Benign prostatic hyperplasia: Diagnosis and treatment. Agency for Health Care Policy and Research. *Clin Pract Guidel Quick Ref Guide Clin* 1994;1-17.
8. Serretta et al. Serretta V, Morgia G, Fondacaro L, et al: Open prostatectomy for benign prostatic enlargement in southern Europe in the late 1990s: A contemporary series of 1800 interventions. *Urology* 2002; 60:623-627.
9. Varkarakis et al., 2004. Varkarakis I, Kyriakakis Z, Delis A, et al: -term results of open Suprapubic prostatectomy from a contemporary series of patients. *Urology* 2004; 64:306-310.
10. Walsh and Oesterling, . Walsh PC, Oesterling JE: Improved hemostasis during simple retropubic prostatectomy. *J Urol* 1990; 143:1203-1204.
11. Min KS, Lee MS. Clinical observation in benign prostatic hyperplasia .*Korean J-Urol* 2004 April 21 (2) 147 -154
12. MoslemiMK, Abdedin Zadeh M. Modified technique of simple prostatectomy. *Qom- Iran. Urology J* 2010 135:212–010
13. J Zargooshi . retropubic prostatectomy: Immediate and postoperative complications ., Kermanshah, Iran. ( Vol. 10 Issue 4 Pg. 374-7 ( 2007) ISSN: 1476-5608 England .
14. Melissari M, Lopez Beltran A, Mazzucchelli R, et al. Advances in the Treatment of Lower Urinary Tract Symptoms and Benign Prostatic Hyperplasia .Rome, Italy. *Rev Urol.* 2006 Fall; 8(4): 216–225. .
15. Kiptoon DK, Magoha GA, Owillah FAMeru, Early postoperative outcomes of patients undergoing prostatectomy for benign prostatic hyperplasia at Kenyatta National Hospital, Nairobi East Africamedical journal (*East Afri Med J*).2007 sep,nol(issue 9suppl); pps40-4 .
16. Trivedi VD –Lokmanya Tilak. A prospective study of the safety and efficacy of retropubic prostatectomy in patients with benign prostatic hyperplasia .*Mumbai–Indian Online since Januray,2006. J Urol* 2001; 166:172-176.